Diabetic Foot and Aortic Disease
How should we manage such patient?

Dr. Nikolaos Melas, PhD
Vascular and Endovascular Surgeon

Military Doctor
Associate in 1st department of Surgery,
Aristotle University of Thessaloniki, Greece
Associate in Interbalcan Medical Center

PAD

- Aortoiliac
- Femoropopliteal
- Distal
- Multifocal
- Combined (with Coronary artery disease, carotid artery disease, renal artery disease and..)

Patterns of aortoiliac occlusive disease

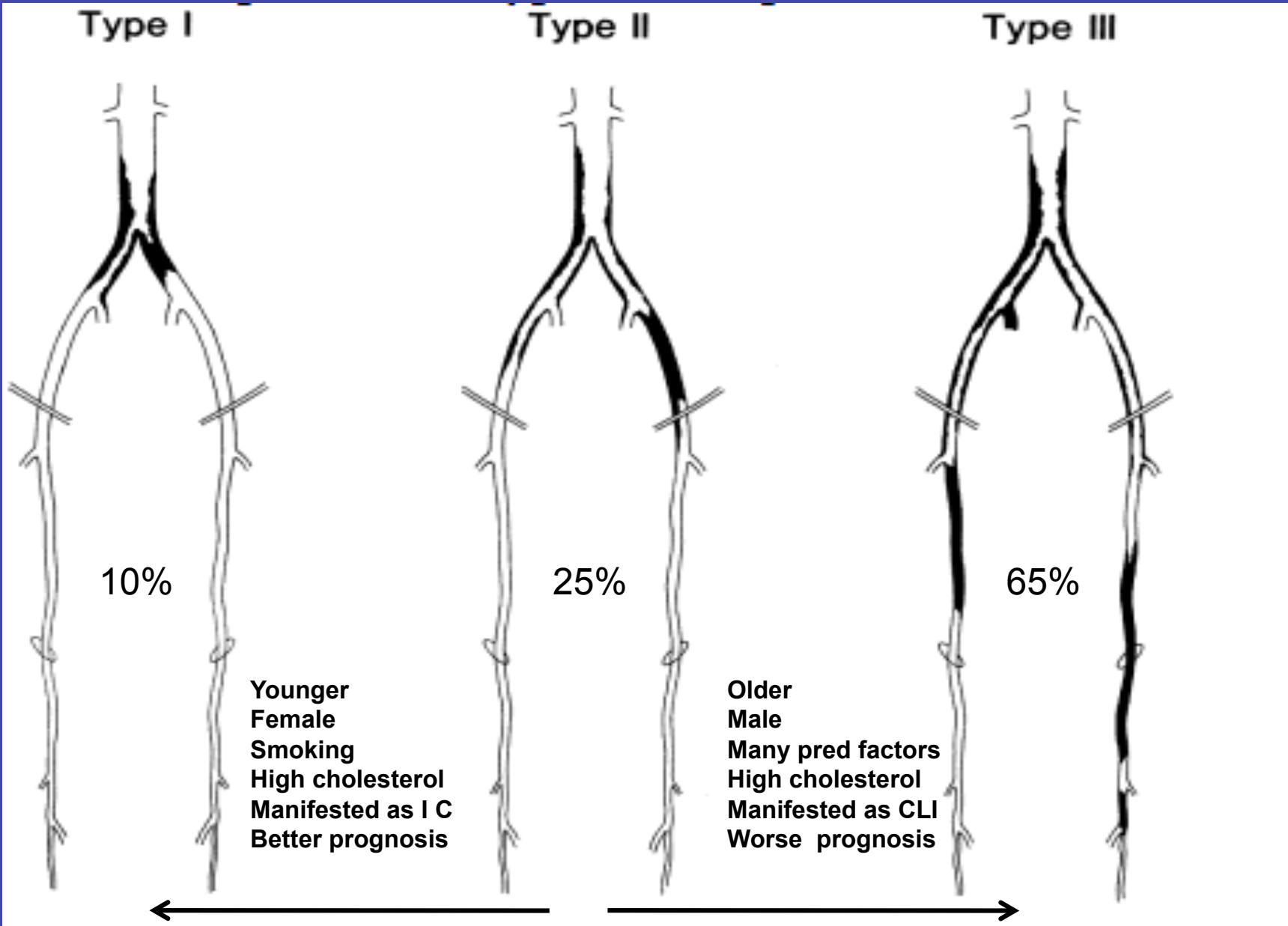

PAD and DM

- DM is not just a major predisposing factor for PAD
- PAD in diabetics comes earlier, is more pronounced and is extended to distal arteries including profounda femoris and distal below knee arteries.
- Has worse prognosis and prompt surgical therapy is mandatory for limb salvage
- DM predisposes to foot infection even upon «normal» distal arterial flow

•Diabetes increases the risk of PAD approximately 3 to 4-fold.

•I Claudication is x 2 in diabetics

•In patients with DM, for every 1% increase in hemoglobin A1c there is a corresponding 26% increased risk of PAD.

•The current ADA recommends hemoglobin A1C of <7.0% as the goal for treatment of diabetes and as close to normal (<6%) as possible without significant hypoglycemia.

•Insulin resistance is a risk factor for PAD even in subjects without diabetes, raising the risk approximately 40% to 50%.

•Diabetes is also associated with peripheral sensory neuropathy, foot osteoarthropathy (Sarco) and decreased resistance to infection, which leads to an increased risk of foot ulcers and foot infections

•The need for a major amputation is x 5 - x10 higher in diabetics than non-diabetics.

•ADA recommends PAD screening with an ABI every 5 years in patients with diabetes.

SELVIN E, MARINOPOULOS S, BERKENBLIT G, RAMI T, BRANCATI FL, POWE NR et al. Meta-analysis: glycosylated hemoglobin and cardiovascular disease in diabetes mellitus. Ann Intern Med 2004; 141(6):421e431.
MUNTNER P, WILDMAN RP, REYNOLDS K, DESALVO KB, CHEN J, FONSECA V. Relationship between HbA1c level and peripheral arterial disease. Diabetes Care 2005;28(8):1981e1987.
ADA. Peripheral arterial disease in people with diabetes.Diabetes Care 2003;26(12):3333e3341.
UKPDS. Intensive blood-glucose control with sulphonylureas or insulin compared with conventional treatment and risk of complications in patients with type 2 diabetes (UKPDS 33). UK Prospective Diabetes Study (UKPDS) Group. Lancet 1998; 352(9131):837e853.
DCCT. Effect of intensive diabetes management on macrovascular events and risk factors in the Diabetes Control and Complications Trial. Am J Cardiol 1995;75(14):894e903.
ADA. Standards of medical care in diabetese2006. Diabetes Care 2006;29(Suppl. 1):S4eS42.
DORMANDY JA, CHARBONNEL B, ECKLAND DJ, ERDMANN E, MASSIBENEDETTI M, MOULES IK et al. Secondary prevention of macrovascular events in patients with type 2 diabetes in the PROactive Study (PROspective pioglitAzone Clinical Trial In macroVascular Events): a randomised controlled trial. Lancet 2005;366(9493):1279e1289.

Recommendation 4. Control of diabetes in peripheral arterial disease (PAD)

- Patients with diabetes and PAD should have aggressive control of blood glucose levels with a hemoglobin A1c goal of <7.0% or as close to 6% as possible [C].

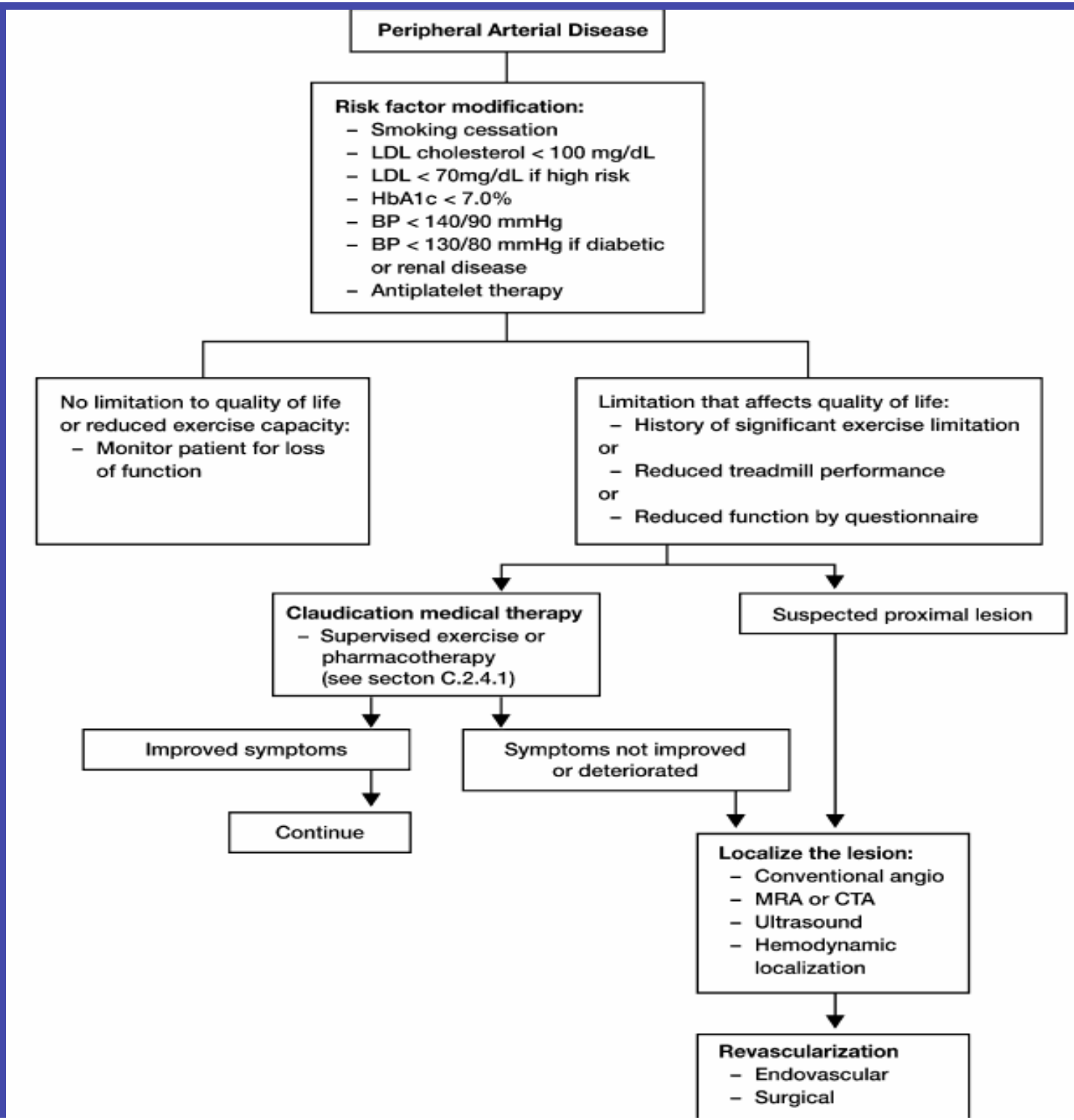
Peripheral Arterial Disease
Risk factor modification:
– Smoking cessation
– LDL cholesterol < 100 mg/dL
– LDL < 70mg/dL if high risk
– HbA1c < 7.0%
– BP < 140/90 mmHg
– BP < 130/80 mmHg if diabetic or renal disease
– Antiplatelet therapy
No limitation to quality of life or reduced exercise capacity:
– Monitor patient for loss of function
Limitation that affects quality of life:
– History of significant exercise limitation
or
– Reduced treadmill performance
or
– Reduced function by questionnaire
Claudication medical therapy
– Supervised exercise or pharmacotherapy (see secton C.2.4.1)
Suspected proximal lesion
Improved symptoms
Symptoms not improved or deteriorated
Continue
Localize the lesion:
– Conventional angio
– MRA or CTA
– Ultrasound
– Hemodynamic localization
Revascularization
– Endovascular
– Surgical

Recommendation 6. Antiplatelet therapy in peripheral arterial disease (PAD)

- All symptomatic patients with or without a history of other cardiovascular disease should be prescribed an antiplatelet drug long term to reduce the risk of cardiovascular morbidity and mortality [A].
- Aspirin/ASA is effective in patients with PAD who also have clinical evidence of other forms of cardiovascular disease (coronary or carotid) [A].
- The use of aspirin/ASA in patients with PAD who do not have clinical evidence of other forms of cardiovascular disease can be considered [C].
- Clopidogrel is effective in reducing cardiovascular events in a subgroup of patients with symptomatic PAD, with or without other clinical evidence of cardiovascular disease [B].

Recommendation 14. Exercise therapy in intermittent claudication

- Supervised exercise should be made available as part of the initial treatment for all patients with peripheral arterial disease [A].
- The most effective programs employ treadmill or track walking that is of sufficient intensity to bring on claudication, followed by rest, over the course of a 30–60 minute session. Exercise sessions are typically conducted three times a week for 3 months [A].

Drugs for IC

- Cilastazol 150mg x 2 daily
- Naftidrofuryl 600 mg/day
- Carnitine, L- Carnitine
- Statins
- Pentoxifylline
- Asp
- Prostaglandins (PGE1)
- Buflomedil
- Growth factor

Recommendation 15. Pharmacotherapy for symptoms of intermittent claudication

- A 3- to 6-month course to determine efficacy of cilostazol should be first-line pharmacotherapy for the relief of claudication symptoms, as evidence shows both an improvement in treadmill exercise performance and in quality of life [A].
- Naftidrofuryl can also be considered for treatment of claudication symptoms [A].

LEHERT P, COMTE S, GAMAND S, BROWN TM. Naftidrofuryl in intermittent claudication: a retrospective analysis. J Cardiovasc Pharmacol 1994;23(Suppl. 3):S48eS52.
BOCCALON H, LEHERT P, MOSNIER M. Effect of naftidrofuryl on physiological walking distance in patients with intermittent claudication. Ann Cardiol Angeiol (Paris) 2001;50(3):175e182.
KIEFFER E, BAHNINI A, MOUREN X, GAMAND S. A new study demonstrates the efficacy of naftidrofuryl in the treatment of intermittent claudication. Findings of the Naftidrofuryl Clinical Ischemia Study (NCIS). Int Angiol 2001;20(1):58e65.
SPENGEL F, CLEMENT D, BOCCALON H, LIARD F, BROWN T, LEHERT P. Findings of the Naftidrofuryl in Quality of Life (NIQOL) European study program. Int Angiol 2002;21(1):20e27.
BREVETTI G, DIEHM C, LAMBERT D. European multicenter study on Propionyl-l-carnitine in intermittent claudication. J Am Coll Cardiol 1999;34:1618e1624.
HIATT W, REGENSTEINER J, CREAGER M, HIRSCH A, COOKE J, OLIN J et al. Propionyl-L-carnitine improves exercise performance and functional status in patients with claudication. Am J Med 2001;110(8):616e622.
MOHLER III E, HIATT W, CREAGER M. Cholesterol reduction with atorvastatin improves walking distance in patients with peripheral arterial disease. Circulation 2003;108(12):1481e1486.
MONDILLO S, BALLO P, BARBATI R, GUERRINI F, AMMATURO T, AGRICOLA E et al. Effects of simvastatin on walking performance and symptoms of intermittent claudication in hypercholesterolemic patients with peripheral vascular disease. Am J Med 2003; 114(5):359e364.
GIROLAMI B, BERNARDI E, PRINS M, TEN CATE J, HETTIARACHCHI R, PRANDONI P et al. Treatment of intermittent claudication with physical training, smoking cessation, pentoxifylline, or nafronyl: a meta-analysis. Arch Intern Med 1999;159(4):337e345.
HOOD SC, MOHER D, BARBER GG. Management of intermittent claudication with pentoxifylline: meta-analysis of randomized controlled trials. CMAJ 1996;155(8):1053e1059.
MOHER D, PHAM B, AUSEJO M, SAENZ A, HOOD S, BARBER G Pharmacological management of intermittent claudication: a metaanalysis of randomised trials. Drugs 2000;59(5):1057e1070.
BELCH J, BELL P, CREISSEN DEA, DORMANDY JA, KESTER RC, MCCOLLUM RD et al. Randomised, placebo-controlled, doubleblind study evaluating the efficacy and safety of AS-013, a prostaglandin E1 prodrug, in patients with intermittent claudication. Circulation 1997;95:2298e2302.
LIEVRE M, MORAND S, BESSE B, FIESSINGER J, BOISSEL J. Oral beraprost sodium, a prostaglandin I(2) analogue, for intermittent claudication: a double-blind, randomized, multicenter controlled trial. Beraprost et Claudication Intermittente (BERCI) Research Group. Circulation 2000;102(4):426e431.
MOHLER III E, HIATT W, OLIN J, WADE M, JEFFS R, HIRSCH A. Treatment of intermittent claudication with beraprost sodium, an orally active prostaglandin I2 analogue: a double-blinded, randomized, controlled trial. J Am Coll Cardiol 2003;41(10): 1679e1686.
DE BACKER T, VANDER STICHELE R, BOGAERT M. Buflomedil for intermittent claudication. Cochrane Database Syst Rev 2001: CD000988.
DE BACKER T, VANDER STICHELE R, WARIE H, BOGAERT M. Oral vasoactive medication in intermittent claudication: utile or futile? Eur J Clin Pharmacol 2000;56(3):199e206
REGENSTEINER J, WARE JJ, MCCARTHY W, ZHANG P, FORBES W, HECKMAN J et al. Effect of cilostazol on treadmill walking, community- based walking ability, and health-related quality of life in patients with intermittent claudication due to peripheral arterial disease: meta-analysis of six randomized controlled trials. J Am Geriatr Soc 2002;50(12):1939e1946.
DAWSON D, CUTLER B, HIATT W, HOBSON R, MARTIN J, BORTEY E et al. A comparison of cilostazol and pentoxifylline for treating intermittent claudication. Am J Med 2000;109(7):523e530.

TBI instead of ABI

long-standing diabetes, renal failure and other disorders resulting in vascular calcification can develop incompressible tibial arteries, which cause falsely high systolic pressures.

Non-compressible measurements are defined as a very elevated ankle pressure (e.g. 250 mmHg) or ankle-brachial index (ABI) >1.40.

Measurement of toe pressures provides an accurate measurement of distal limb systolic pressures in vessels that do not typically become non-compressible. A special small cuff is used proximally on the first or second toe with a flow sensor, such as that used for digital plethysmography.

The toe pressure is normally approximately 30 mmHg less than the ankle pressure and an abnormal toe-brachial index (TBI) is <0.70.

False positive results with the TBI are unusual. The main limitation in patients with diabetes is that it may be impossible to measure toe pressure in the first and second toes due to inflammatory lesions, ulceration, or loss of tissue.

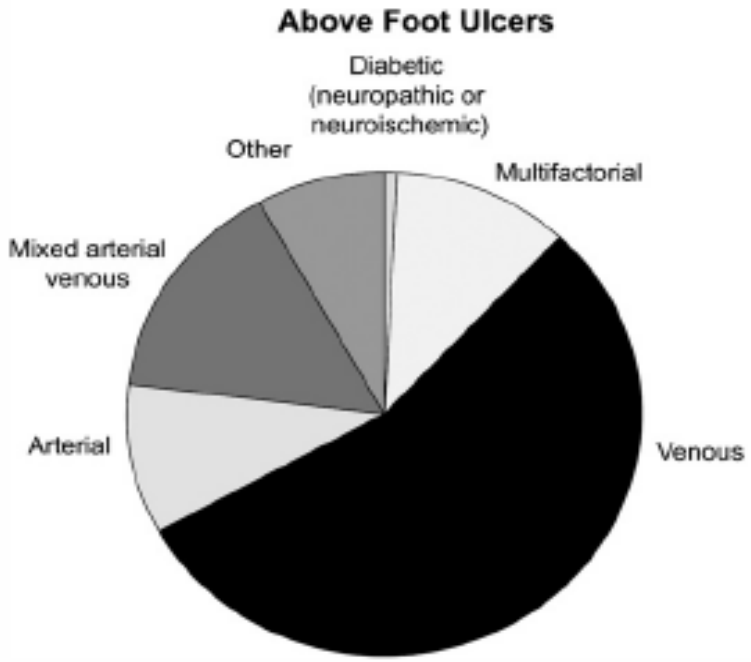

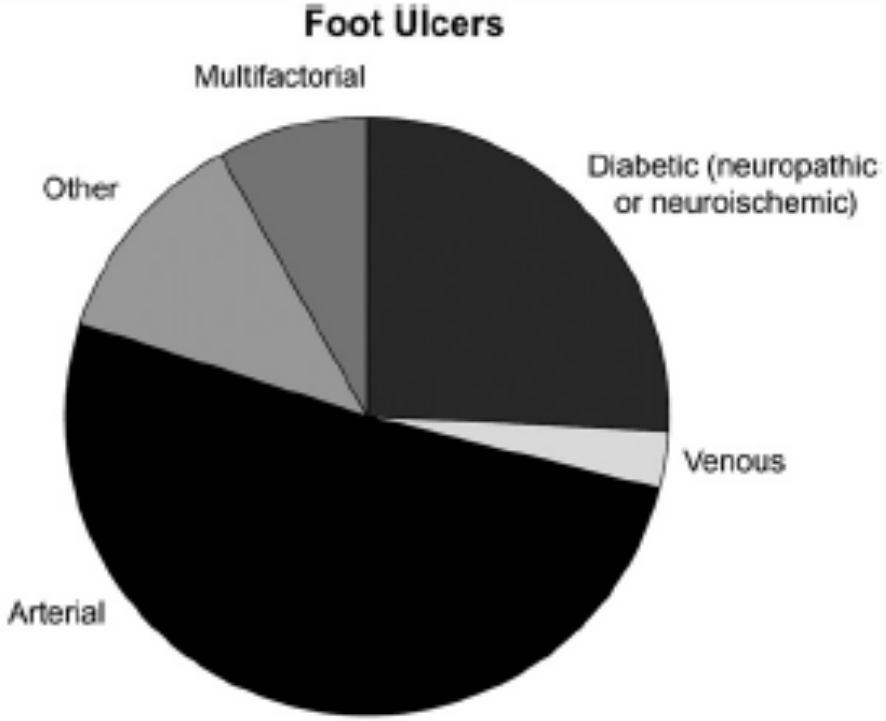

Fig. D1. Approximate frequencies of various ulcer etiologies.

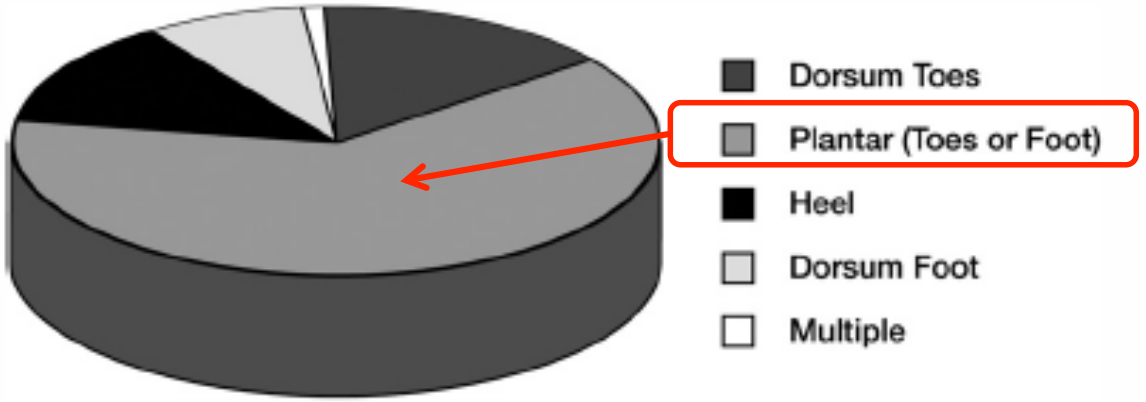

Fig. D2. Distribution of diabetic foot ulcers.[125] Copyright © 1999 American Diabetes Association from *Diabetes Care*, Vol. 22, 1999; 157–162. Modified with permission from The American Diabetes Association.

PATHOGENESIS OF DIABETIC FOOT ULCER AND AMPUTATION

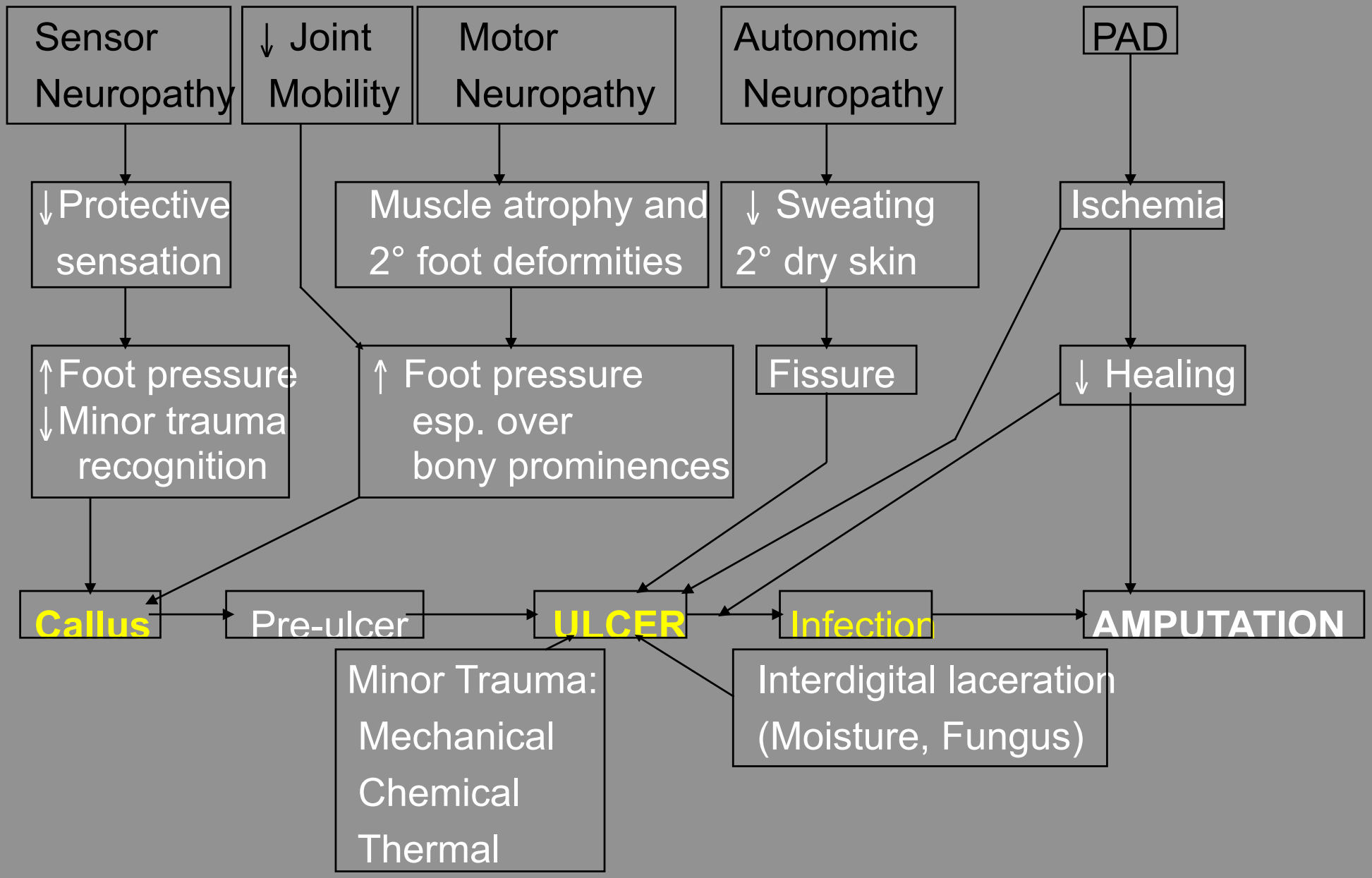

MOTOR NEUROPATHY AND FOOT DEFORMITIES

- Hammer toes
- **Claw toes**
- **Prominent metatarsal heads**
- Hallux valgus
- Collapsed plantar arch

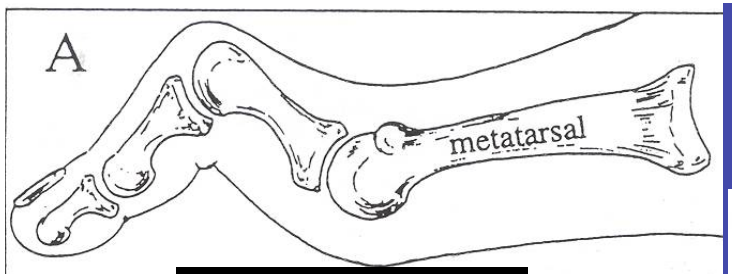

Hammer Toes

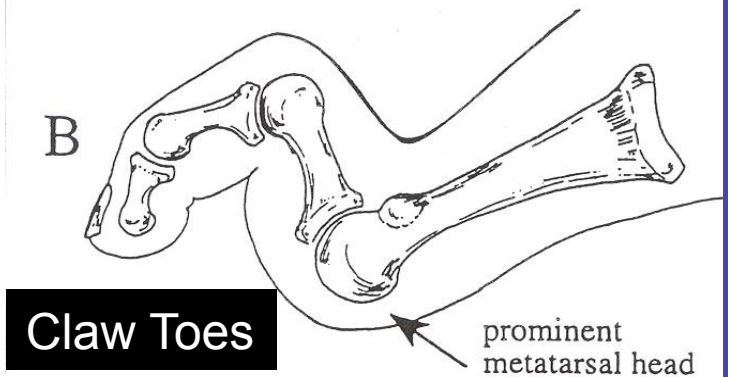

Claw Toes

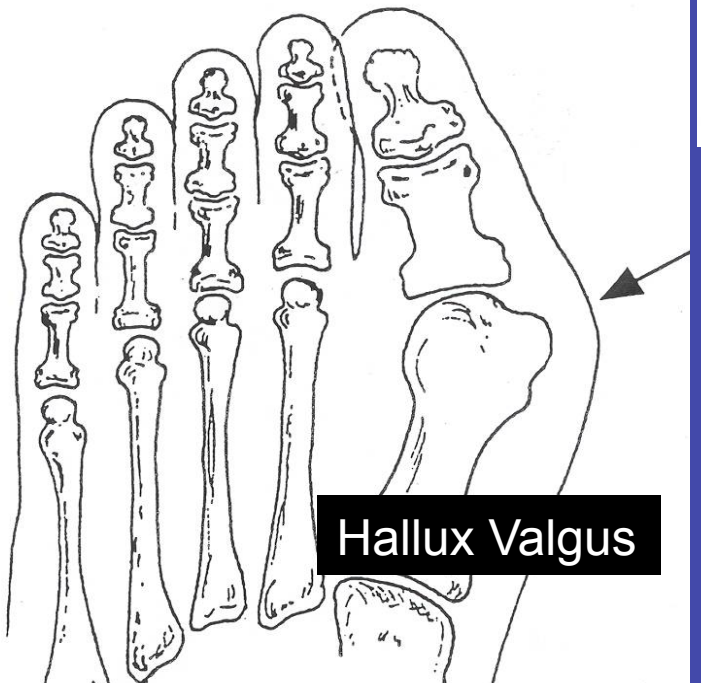

Hallux Valgus

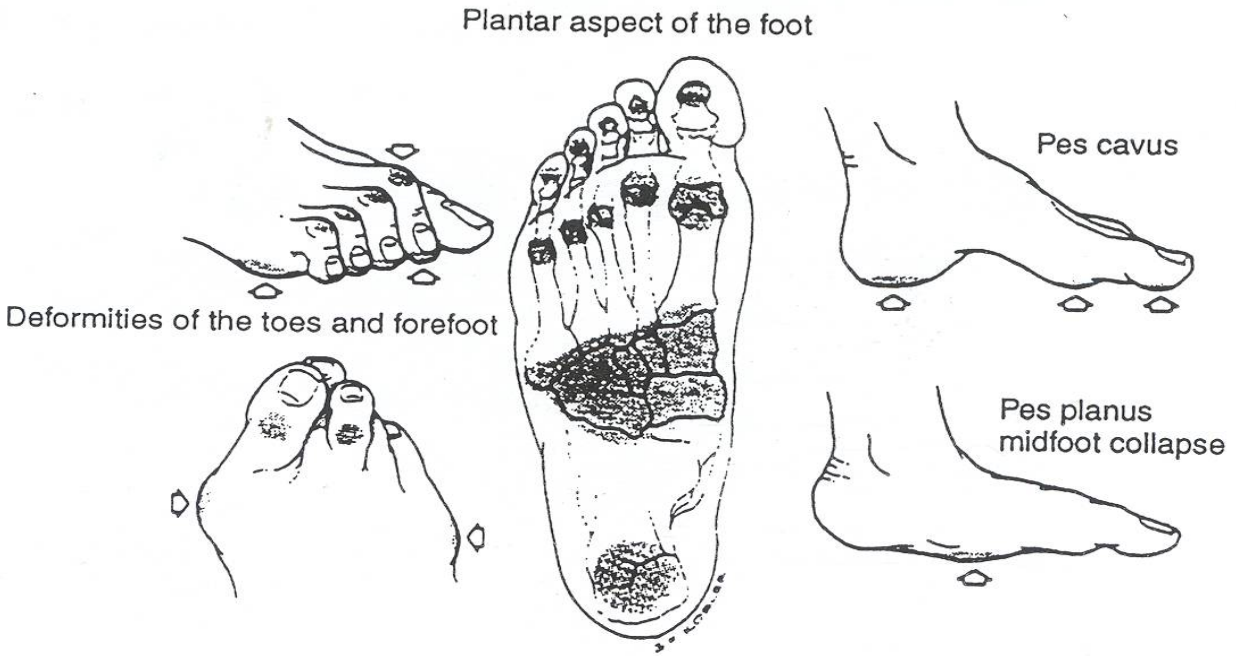

From Boulton, et al Diabetic Medicine 1998, 15:508

From Levin and Pfeifer, The Uncomplicated Guide to Diabetes Complications, 2002

©2006. American College of Physicians. All Rights Reserved.

Hallux valgus deformity and early hammer-toe deformities from diabetic motor neuropathy

©2006. American College of Physicians. All Rights Reserved.

hammer and claw-toe deformities

©2006. American College of Physicians. All Rights Reserved.

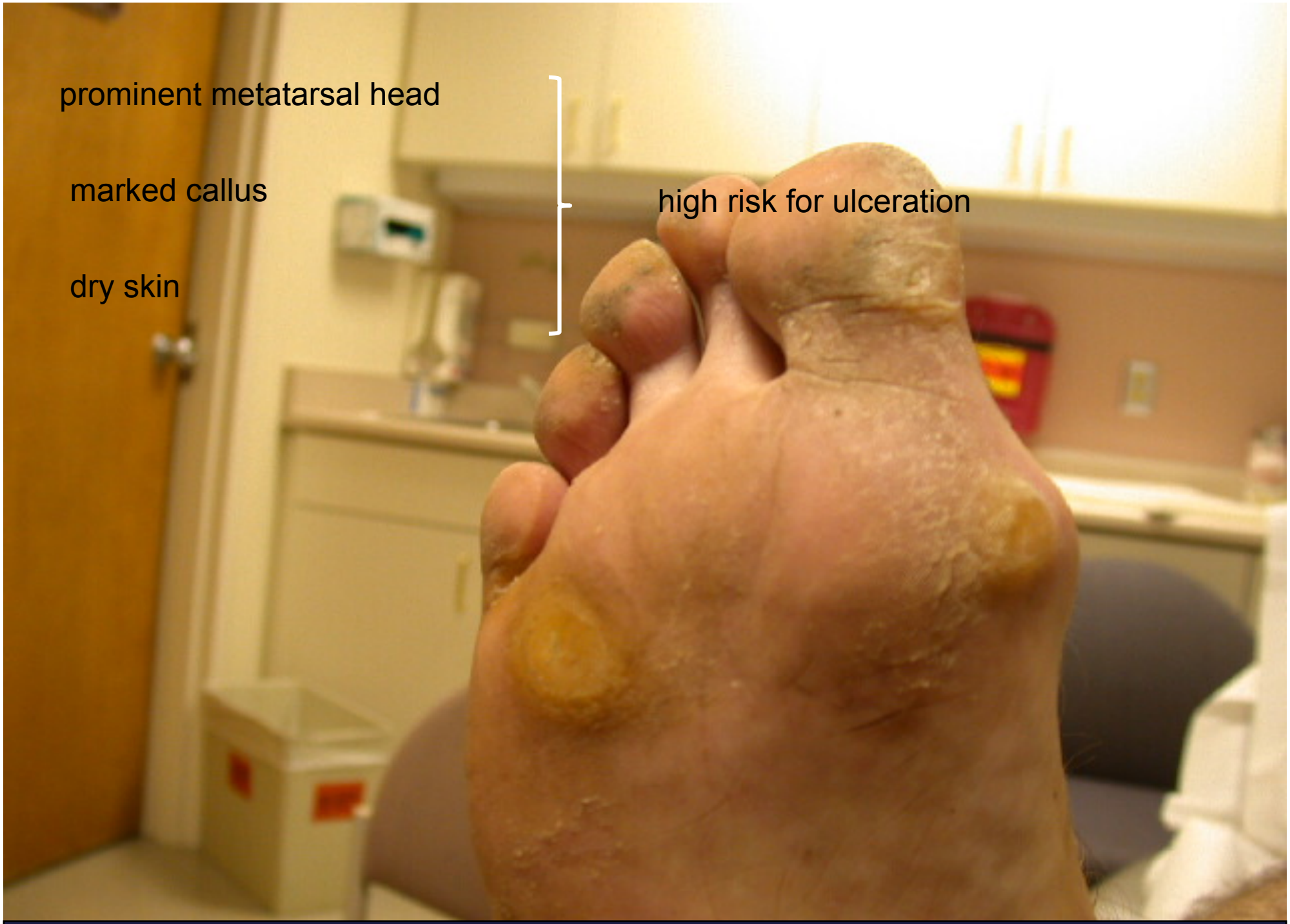

©2006. American College of Physicians. All Rights Reserved.

©2006. American College of Physicians. All Rights Reserved.

©2006. American College of Physicians. All Rights Reserved.

©2006. American College of Physicians. All Rights Reserved.

©2006. American College of Physicians. All Rights Reserved.

©2006. American College of Physicians. All Rights Reserved.

©2006. American College of Physicians. All Rights Reserved.

Diabetic foot infection and aorto iliac disease

How should we manage such patient?

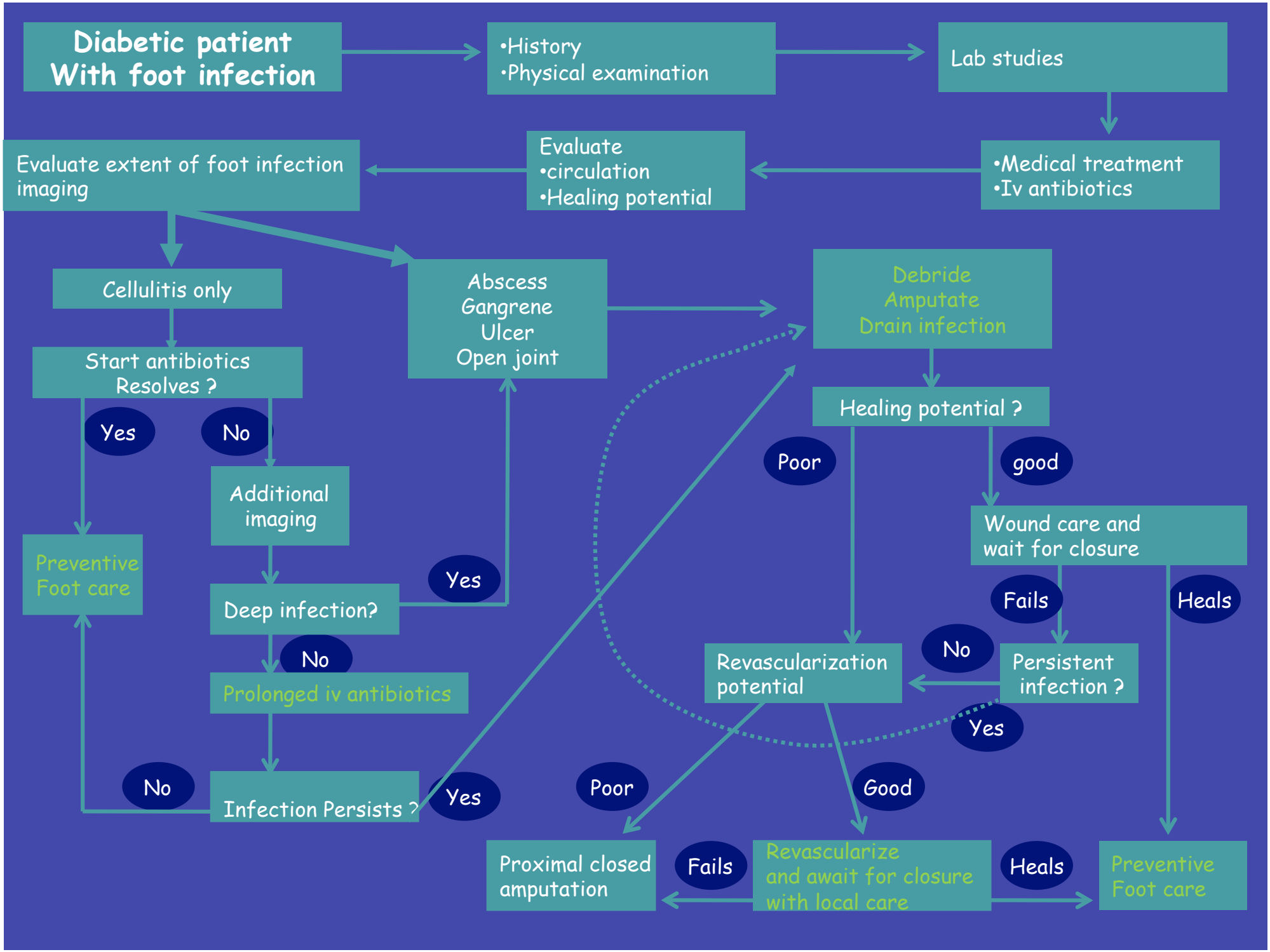
Diabetic patient
With foot infection
•History
•Physical examination
Lab studies
•Medical treatment
•Iv antibiotics
Evaluate
•circulation
•Healing potential
Evaluate extent of foot infection
imaging
Cellulitis only
Start antibiotics
Resolves ?
Yes
No
Additional
imaging
Deep infection?
Yes
No
Prolonged iv antibiotics
Infection Persists ?
Yes
No
Preventive
Foot care
Abscess
Gangrene
Ulcer
Open joint
Debride
Amputate
Drain infection
Healing potential ?
Poor
good
Wound care and
wait for closure
Fails
Heals
Persistent
infection ?
No
Yes
Revascularization
potential
Poor
Good
Proximal closed
amputation
Fails
Revascularize
and await for closure
with local care
Heals
Preventive
Foot care

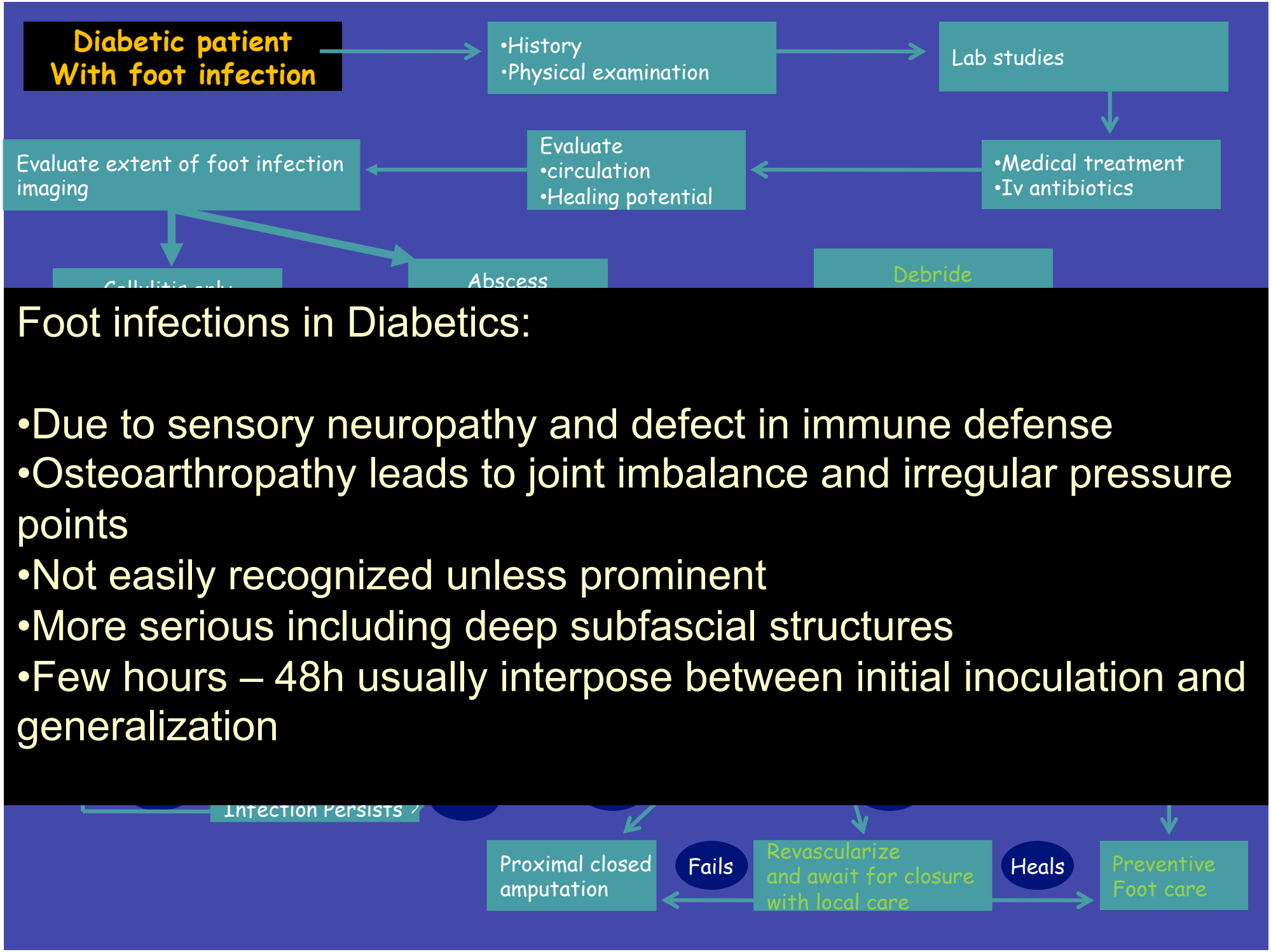

Foot infections in Diabetics:

- Due to sensory neuropathy and defect in immune defense
- Osteoarthropathy leads to joint imbalance and irregular pressure points
- Not easily recognized unless prominent
- More serious including deep subfascial structures
- Few hours – 48h usually interpose between initial inoculation and generalization

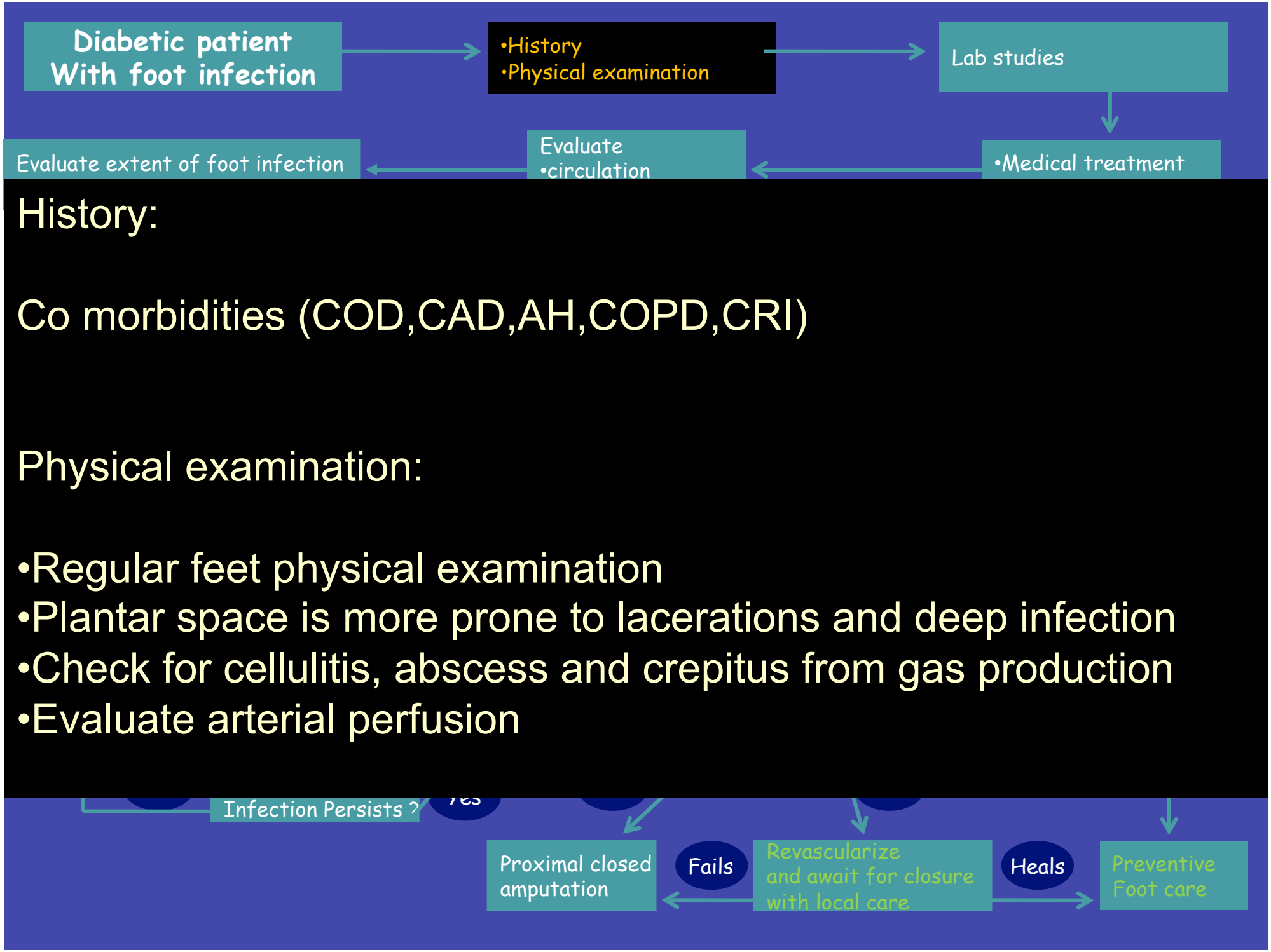

History:

Co morbidities (COD,CAD,AH,COPD,CRI)

Physical examination:

- Regular feet physical examination
- Plantar space is more prone to lacerations and deep infection
- Check for cellulitis, abscess and crepitus from gas production
- Evaluate arterial perfusion

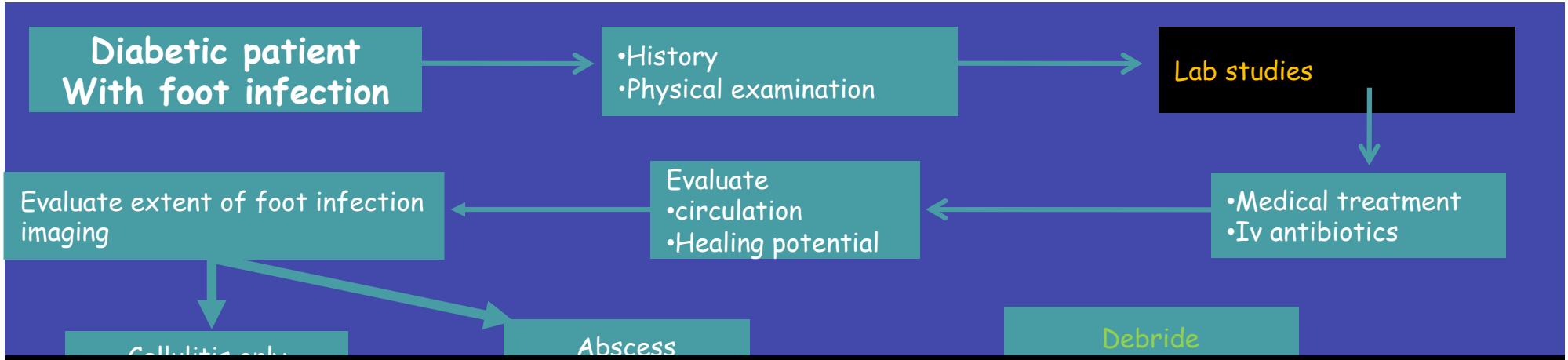

•WBC, CRP, ESR, blood glucose level, electrolytes, Urea Nitrogen, creatinine

•ECG

•Diabetic foot + uncontrolled blood glucose → EMERGENCY (septicemia and septic shock)

Fluid resuscitation
Iv antibiotic
Hyperglycemia control
Cardiovascular instability correction

8-12 h before surgical intervention

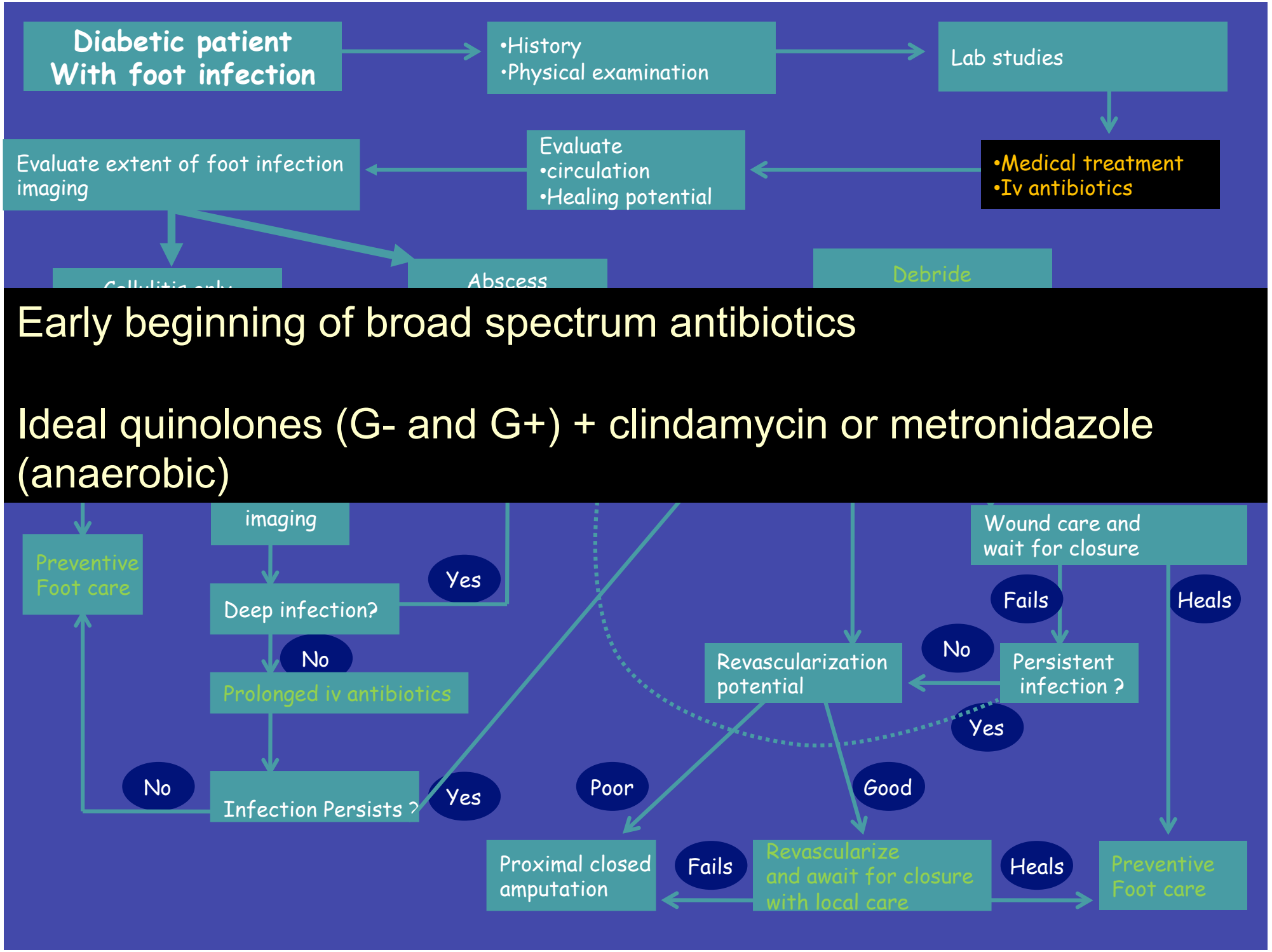
Diabetic patient
With foot infection
•History
•Physical examination
Lab studies
•Medical treatment
•Iv antibiotics
Evaluate
•circulation
•Healing potential
Evaluate extent of foot infection
imaging
Abscess
Debride
Early beginning of broad spectrum antibiotics
Ideal quinolones (G- and G+) + clindamycin or metronidazole (anaerobic)
imaging
Preventive
Foot care
Yes
Deep infection?
No
Prolonged iv antibiotics
No
Infection Persists ?
Yes
Wound care and
wait for closure
Fails
Heals
No
Revascularization
potential
Persistent
infection ?
Yes
Poor
Good
Proximal closed
amputation
Fails
Revascularize
and await for closure
with local care
Heals
Preventive
Foot care

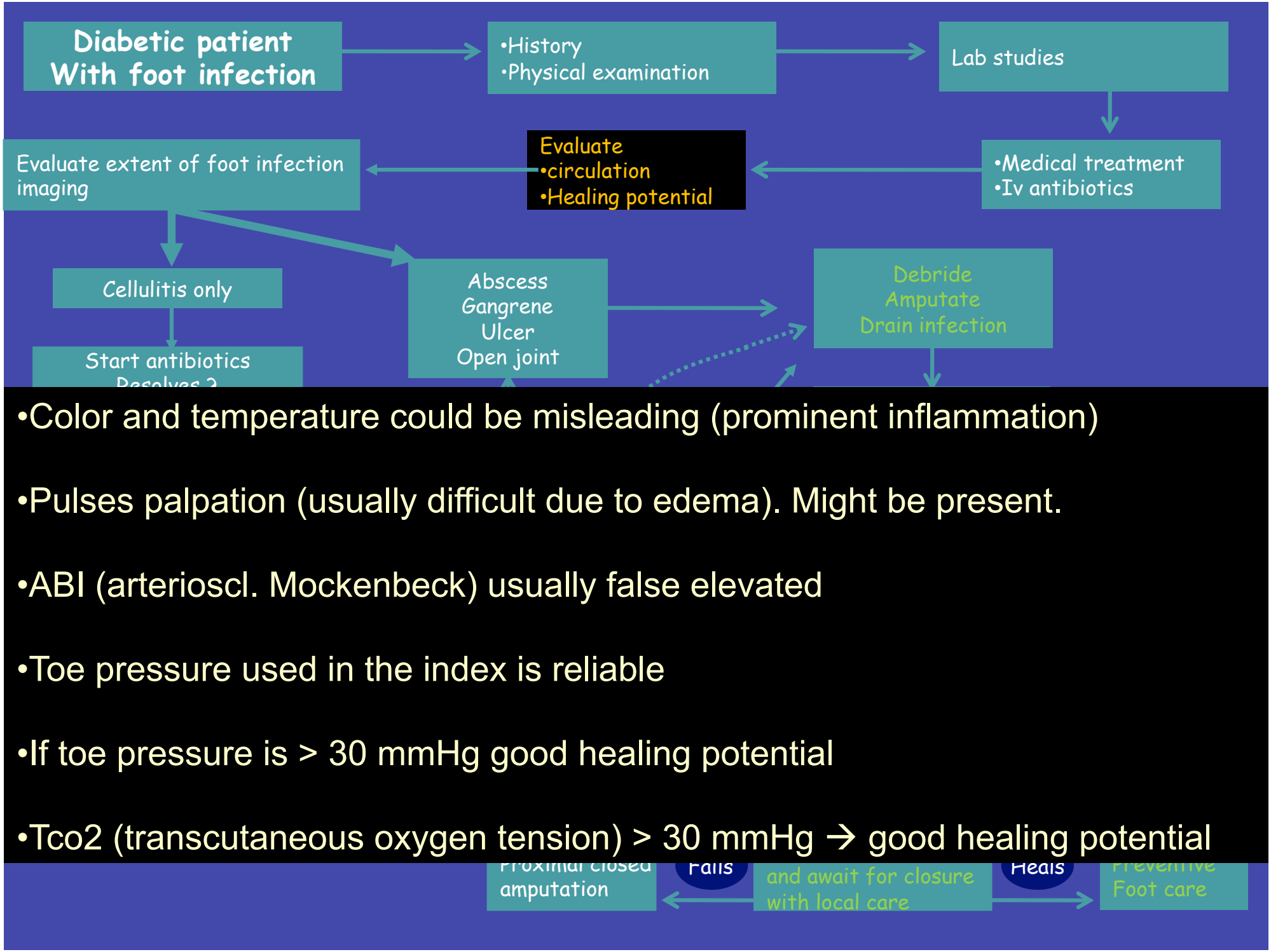
Diabetic patient
With foot infection
•History
•Physical examination
Lab studies
•Medical treatment
•Iv antibiotics
Evaluate
•circulation
•Healing potential
Evaluate extent of foot infection
imaging
Cellulitis only
Start antibiotics
Abscess
Gangrene
Ulcer
Open joint
Debride
Amputate
Drain infection
•Color and temperature could be misleading (prominent inflammation)
•Pulses palpation (usually difficult due to edema). Might be present.
•ABI (arterioscl. Mockenbeck) usually false elevated
•Toe pressure used in the index is reliable
•If toe pressure is > 30 mmHg good healing potential
•Tco2 (transcutaneous oxygen tension) > 30 mmHg → good healing potential
amputation
Fails
and await for closure
with local care
Heals
Foot care

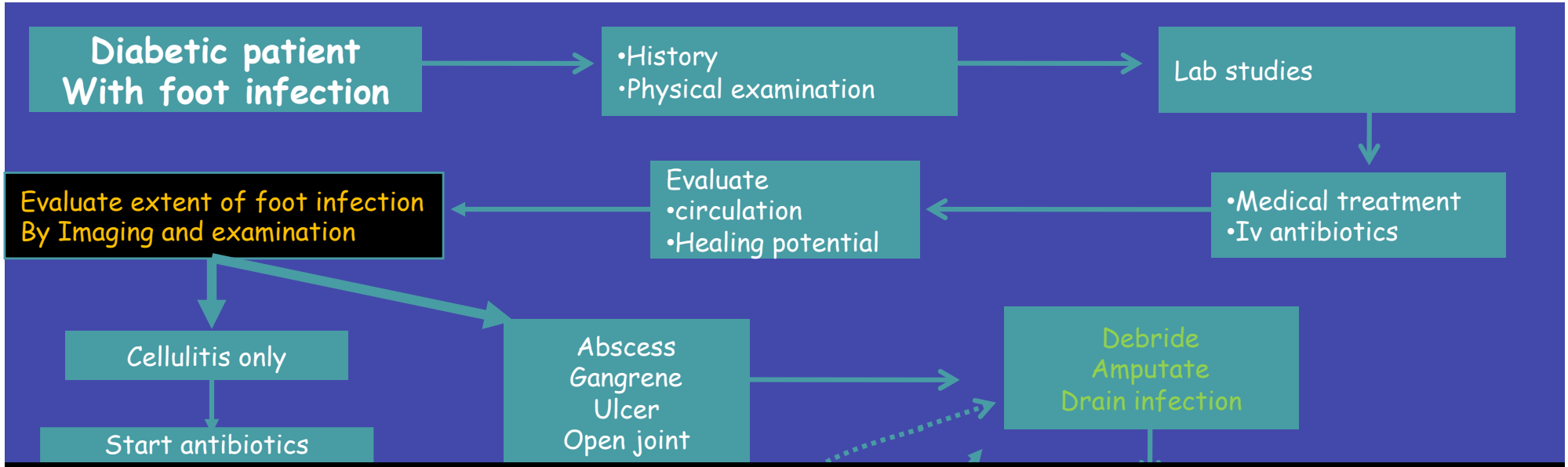

Foot X-rays (f, p, oblique) under magnification:

Gas in soft tissue
Osteomyelitis (unfortunately insensitive)

MRI:

Sensitive from initial stage of osteomyelitis
But not first line scan
Usually in persistent foot infection

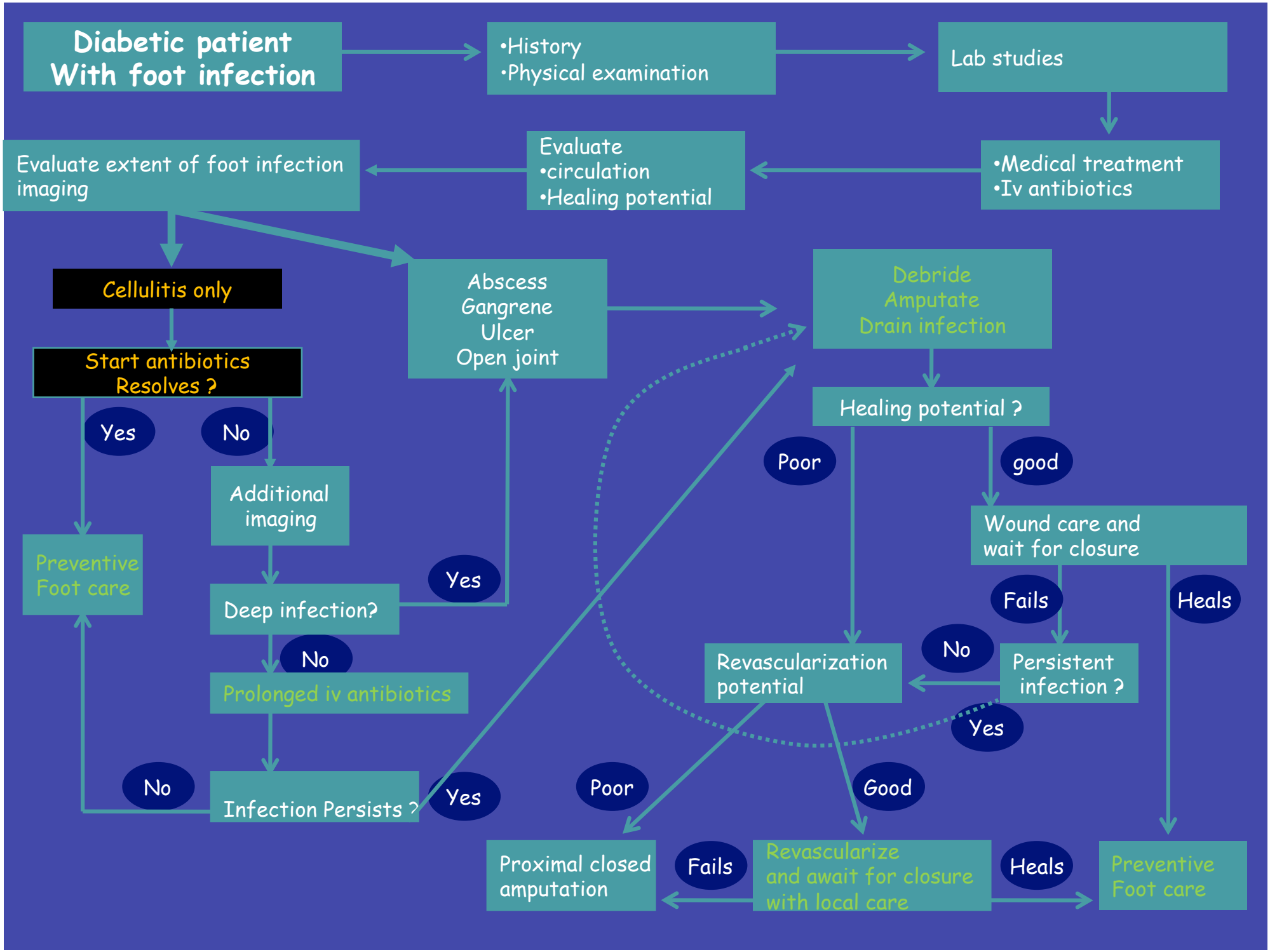
Diabetic patient
With foot infection
•History
•Physical examination
Lab studies
•Medical treatment
•Iv antibiotics
Evaluate
•circulation
•Healing potential
Evaluate extent of foot infection
imaging
Cellulitis only
Start antibiotics
Resolves ?
Yes
No
Preventive
Foot care
Additional
imaging
Deep infection?
Yes
No
Prolonged iv antibiotics
Infection Persists ?
Yes
No
Abscess
Gangrene
Ulcer
Open joint
Debride
Amputate
Drain infection
Healing potential ?
Poor
good
Wound care and
wait for closure
Fails
Heals
Persistent
infection ?
No
Revascularization
potential
Yes
Poor
Good
Proximal closed
amputation
Fails
Revascularize
and await for closure
with local care
Heals
Preventive
Foot care

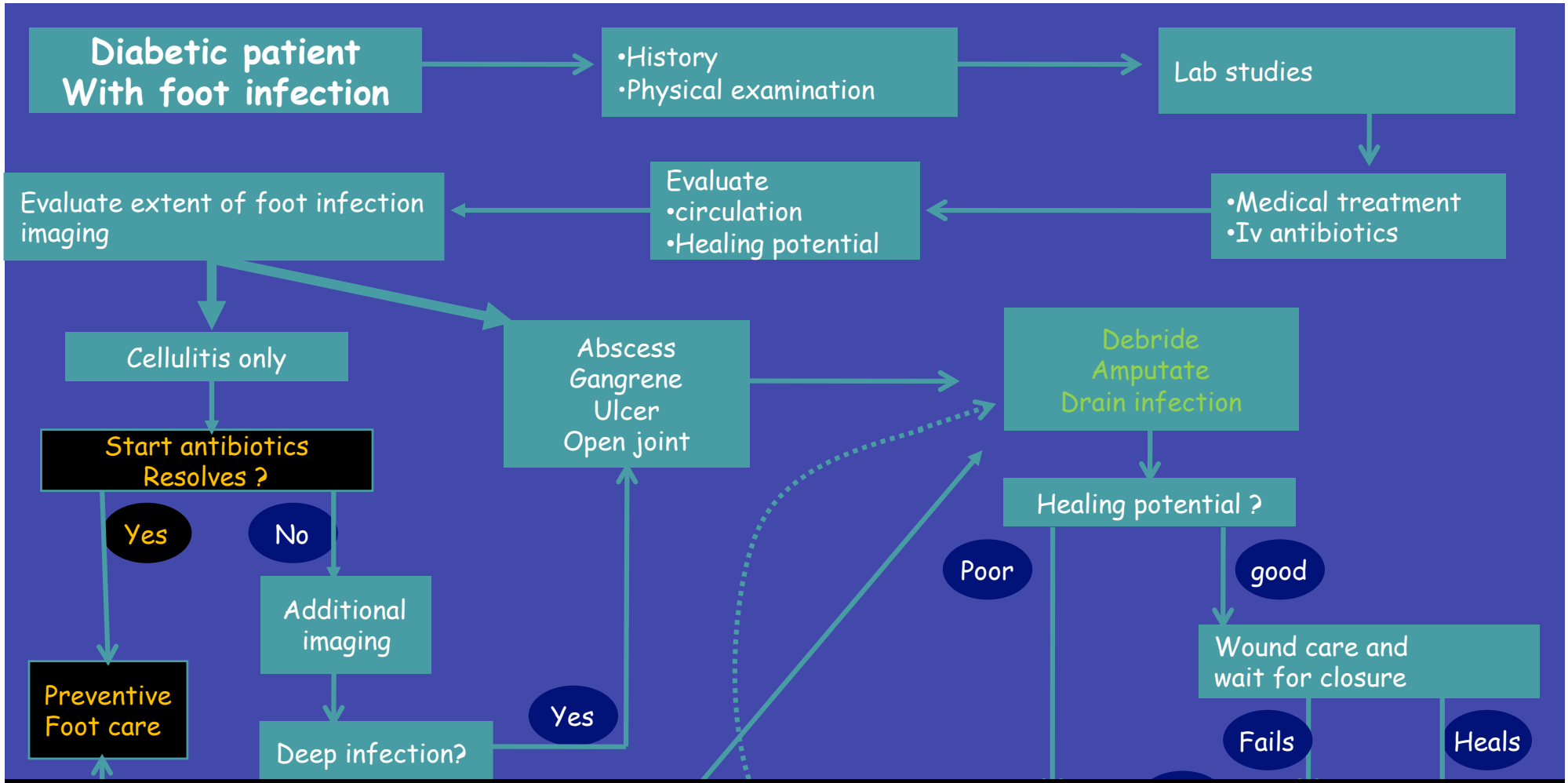

- Insensate foot should be regularly checked for laceration or initial stage inflammation
- Podiatry, calluses care
- Foot hydration
- Proper shoes (distribute weight off sensitive locations such as protruding metatarsal heads)

MRI:

- Closed spaces with abscess
- Deep tissue infection
- Osteomyelitis (osteopenia, disturbance in cortex and medulla)
- Beware of late onset osteomyelitis (2 weeks after inflammation)

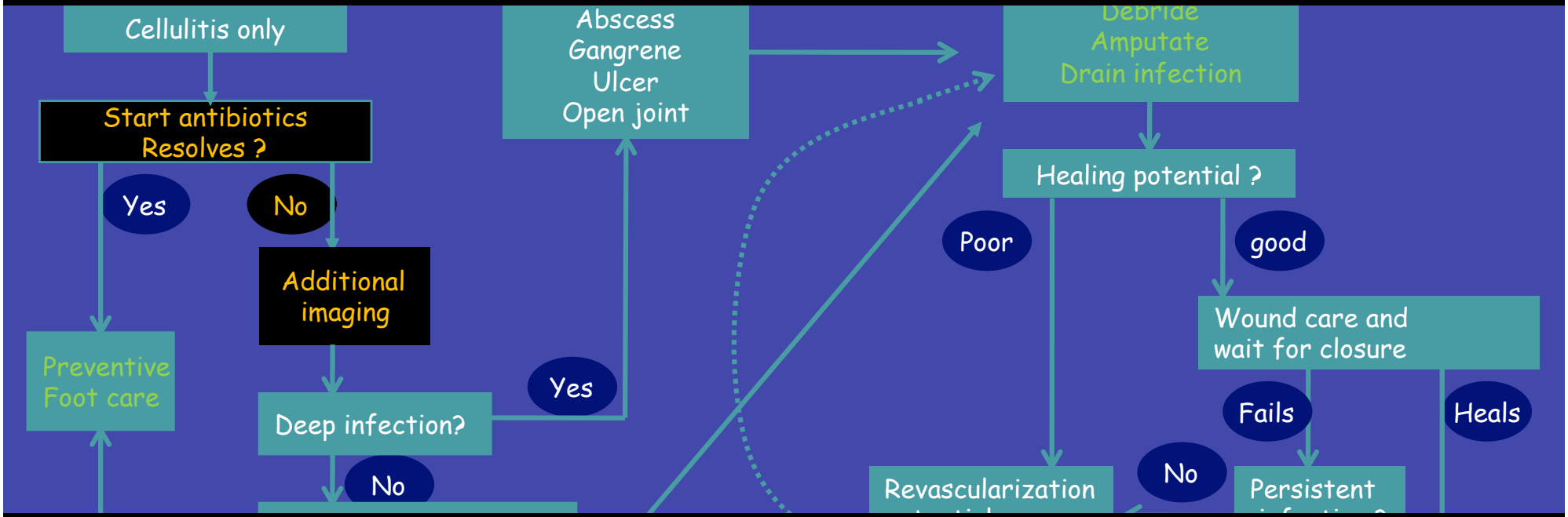

Scintigraphy:

- Technetium (early osteomyel. detection within days)
- Gallium
- Indium labeled WBC

- Aggressive antibiotic therapy
- Careful local monitoring for worsening

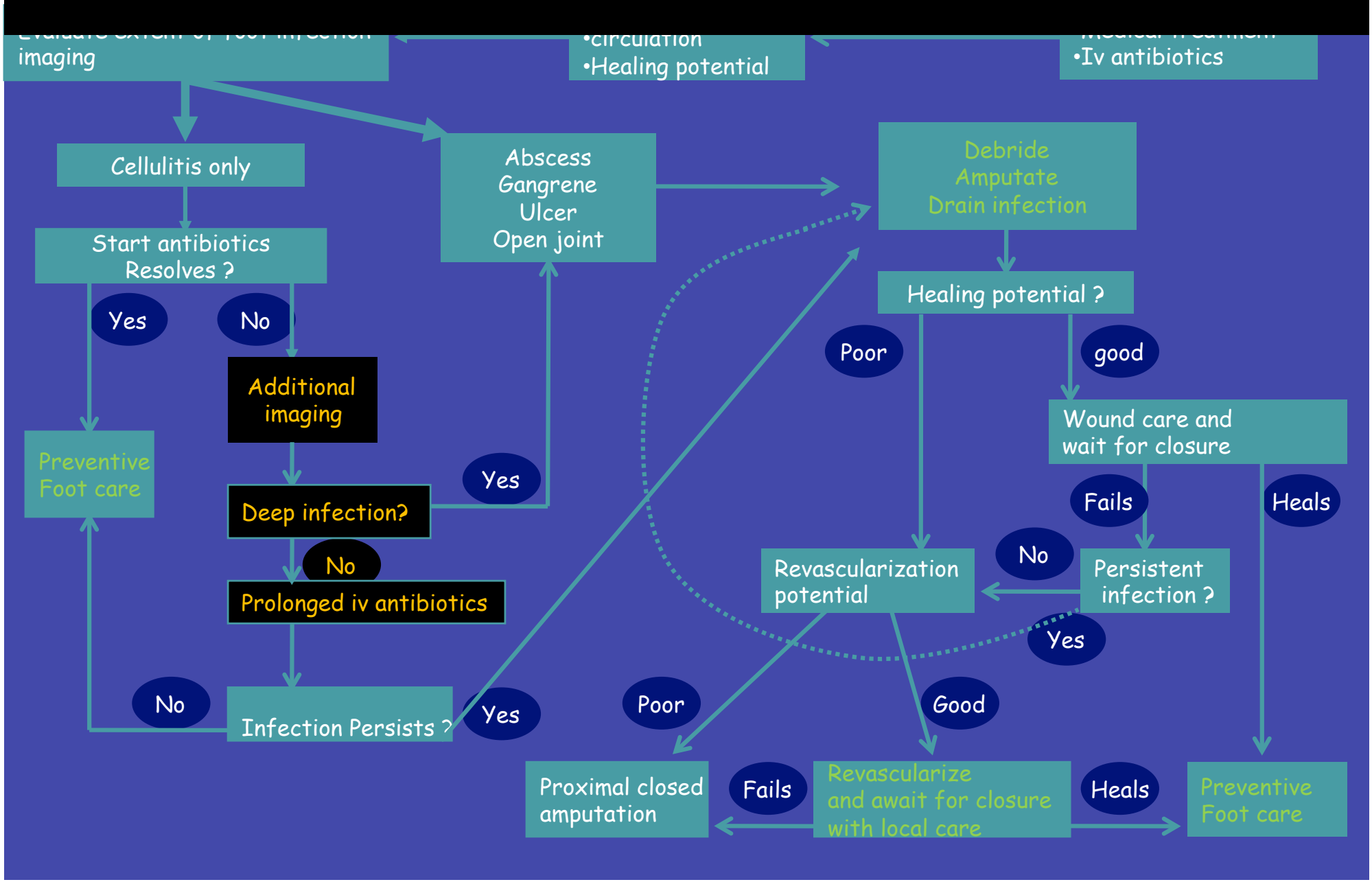

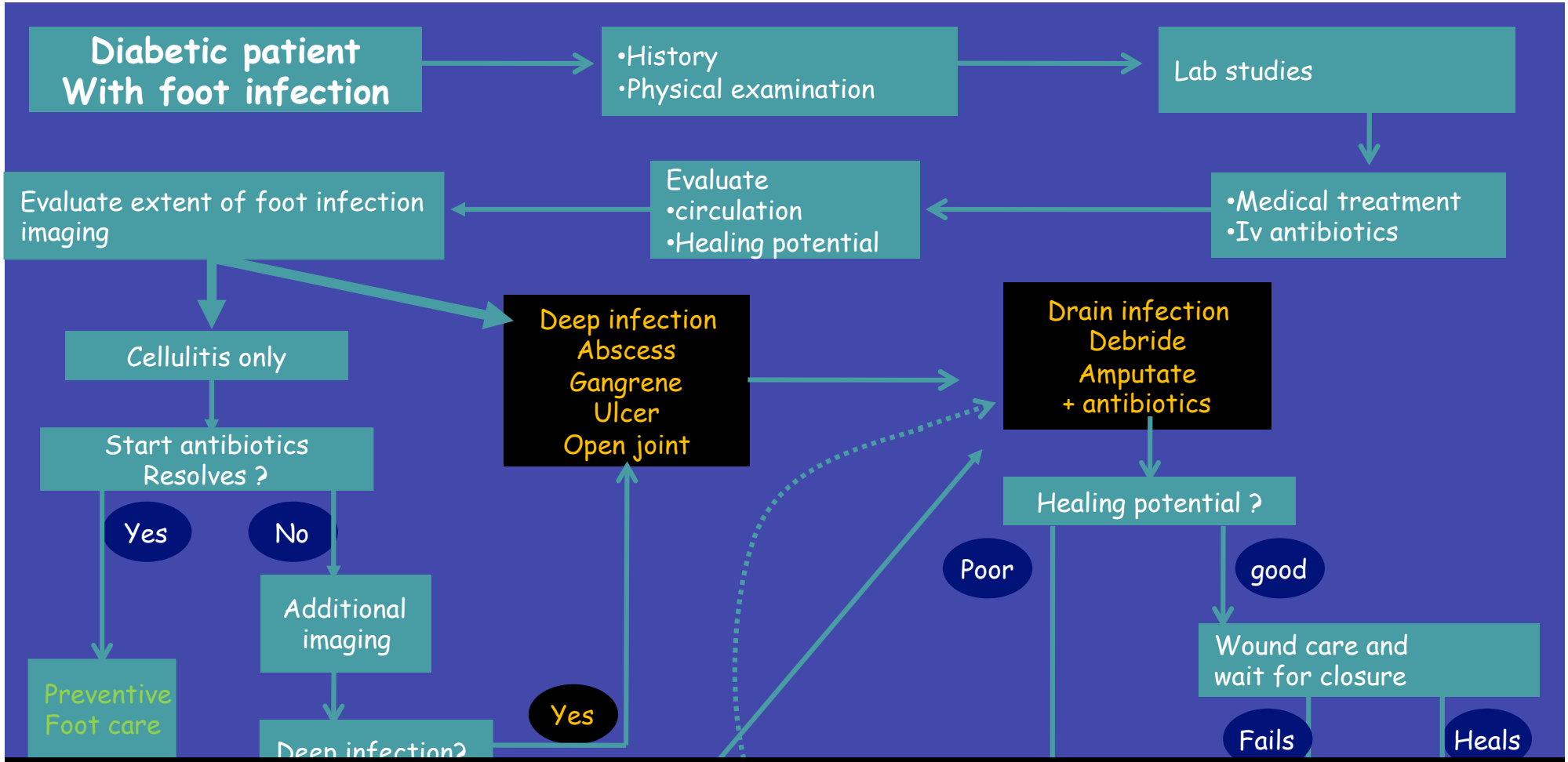

- Drain every closed cavity and subfascial space
- Remove all necrotizing tissue
- Remove tendons
- Remove devitalized / osteom. bones
- VAC sometimes helpful
- Let the wound open to granulate with every day local care

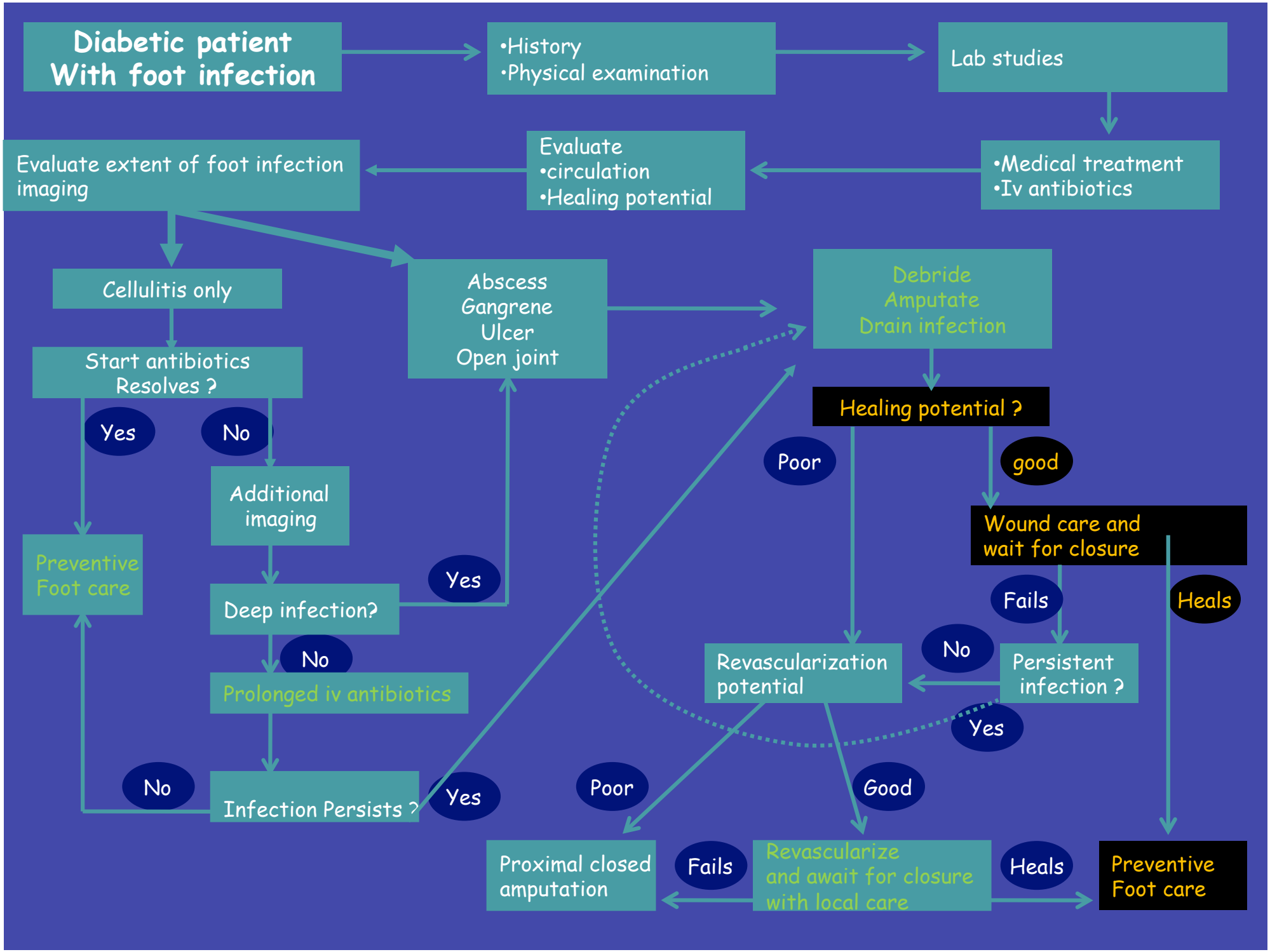
Diabetic patient
With foot infection
•History
•Physical examination
Lab studies
•Medical treatment
•Iv antibiotics
Evaluate
•circulation
•Healing potential
Evaluate extent of foot infection
imaging
Cellulitis only
Start antibiotics
Resolves ?
Yes
No
Preventive
Foot care
Additional
imaging
Deep infection?
Yes
No
Prolonged iv antibiotics
Infection Persists ?
Yes
No
Abscess
Gangrene
Ulcer
Open joint
Debride
Amputate
Drain infection
Healing potential ?
Poor
good
Wound care and
wait for closure
Fails
Heals
Persistent
infection ?
No
Revascularization
potential
Yes
Poor
Good
Proximal closed
amputation
Fails
Revascularize
and await for closure
with local care
Heals
Preventive
Foot care

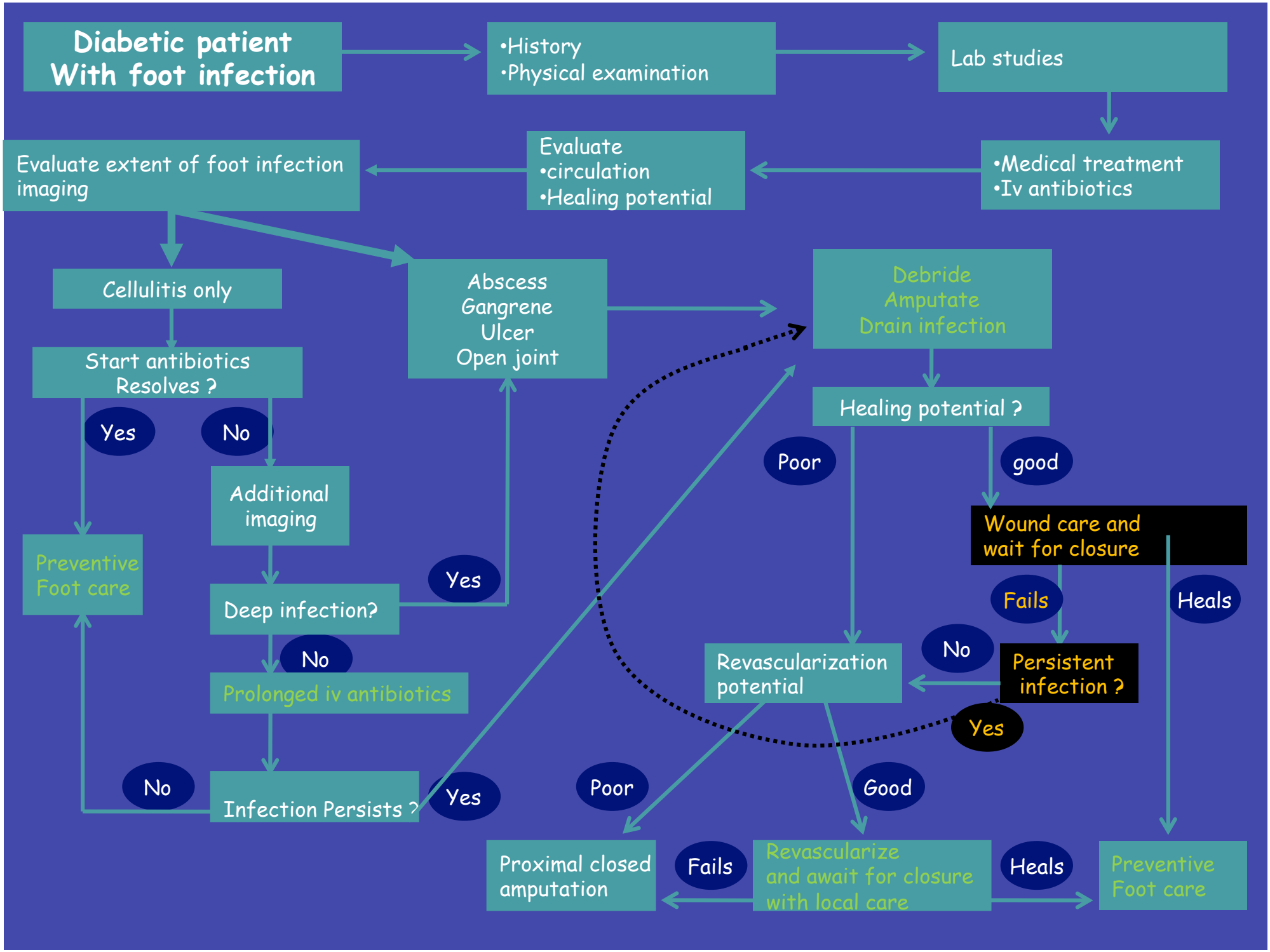
Diabetic patient
With foot infection
•History
•Physical examination
Lab studies
•Medical treatment
•Iv antibiotics
Evaluate
•circulation
•Healing potential
Evaluate extent of foot infection
imaging
Cellulitis only
Abscess
Gangrene
Ulcer
Open joint
Debride
Amputate
Drain infection
Start antibiotics
Resolves ?
Yes
No
Additional
imaging
Preventive
Foot care
Deep infection?
Yes
No
Prolonged iv antibiotics
No
Infection Persists ?
Yes
Healing potential ?
Poor
good
Wound care and
wait for closure
Fails
Heals
No
Revascularization
potential
Persistent
infection ?
Yes
Poor
Good
Proximal closed
amputation
Fails
Revascularize
and await for closure
with local care
Heals
Preventive
Foot care

- U/S (triplex)
- MRA
- CTA?
- DSA

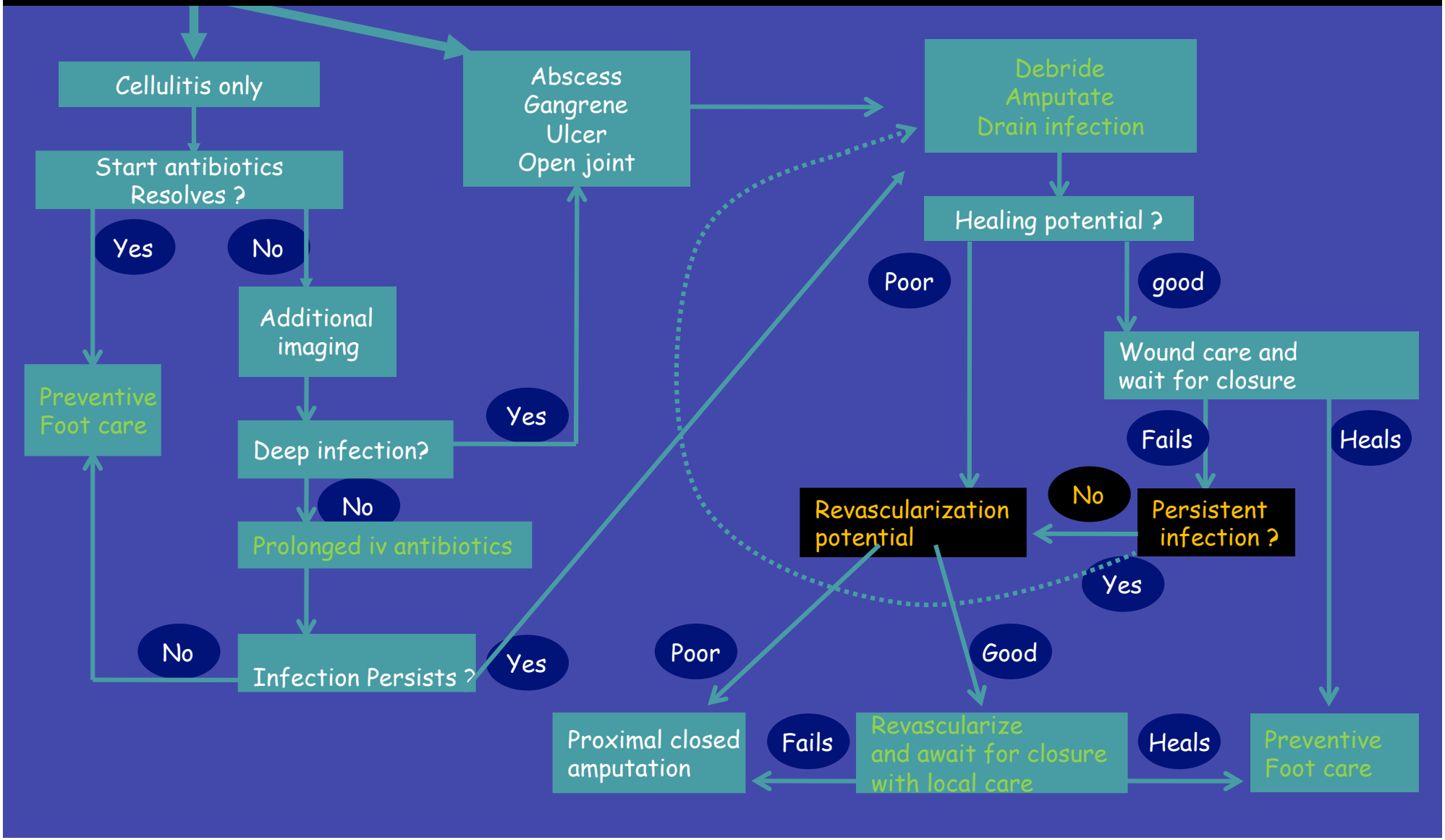

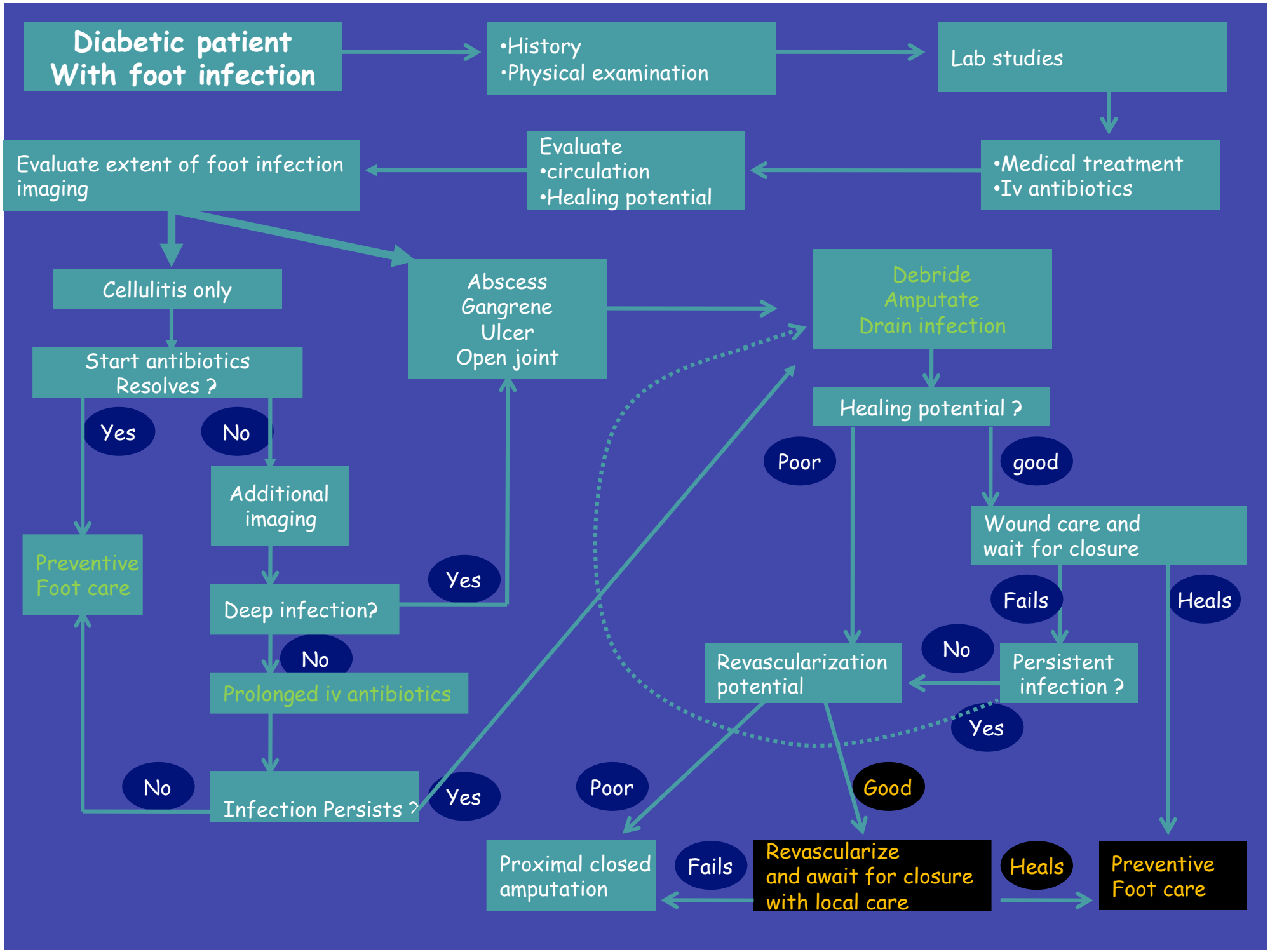
Diabetic patient
With foot infection
•History
•Physical examination
Lab studies
•Medical treatment
•Iv antibiotics
Evaluate
•circulation
•Healing potential
Evaluate extent of foot infection
imaging
Cellulitis only
Start antibiotics
Resolves ?
Yes
No
Preventive
Foot care
Additional
imaging
Deep infection?
Yes
No
Prolonged iv antibiotics
Infection Persists ?
Yes
No
Abscess
Gangrene
Ulcer
Open joint
Debride
Amputate
Drain infection
Healing potential ?
Poor
good
Wound care and
wait for closure
Fails
Heals
Persistent
infection ?
No
Yes
Revascularization
potential
Poor
Good
Proximal closed
amputation
Fails
Revascularize
and await for closure
with local care
Heals
Preventive
Foot care

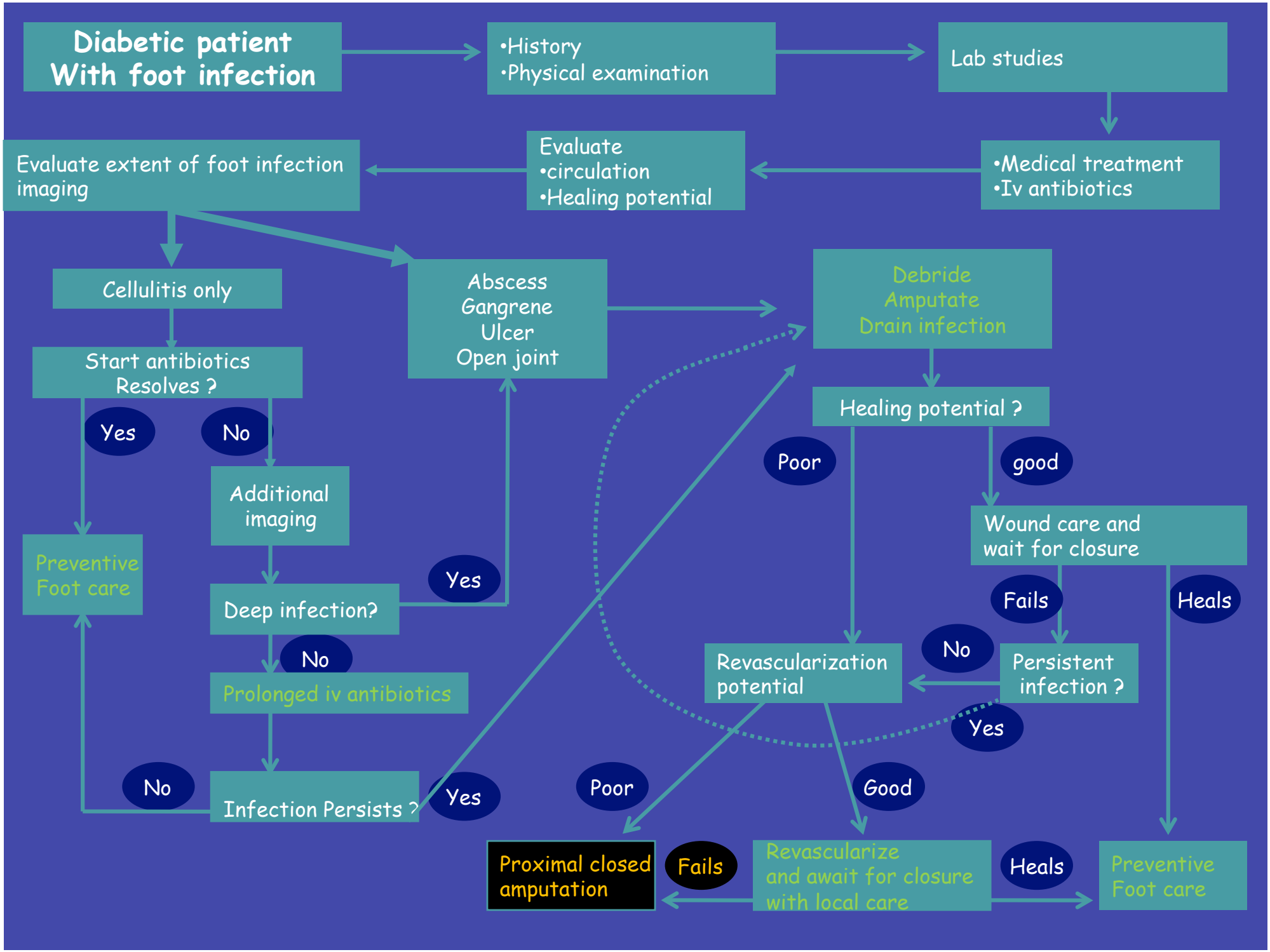
Diabetic patient
With foot infection
•History
•Physical examination
Lab studies
•Medical treatment
•Iv antibiotics
Evaluate
•circulation
•Healing potential
Evaluate extent of foot infection
imaging
Cellulitis only
Start antibiotics
Resolves ?
Yes
No
Preventive
Foot care
Additional
imaging
Deep infection?
Yes
No
Prolonged iv antibiotics
Infection Persists ?
Yes
No
Abscess
Gangrene
Ulcer
Open joint
Debride
Amputate
Drain infection
Healing potential ?
Poor
good
Wound care and
wait for closure
Fails
Heals
Persistent
infection ?
No
Yes
Revascularization
potential
Poor
Good
Proximal closed
amputation
Fails
Revascularize
and await for closure
with local care
Heals
Preventive
Foot care

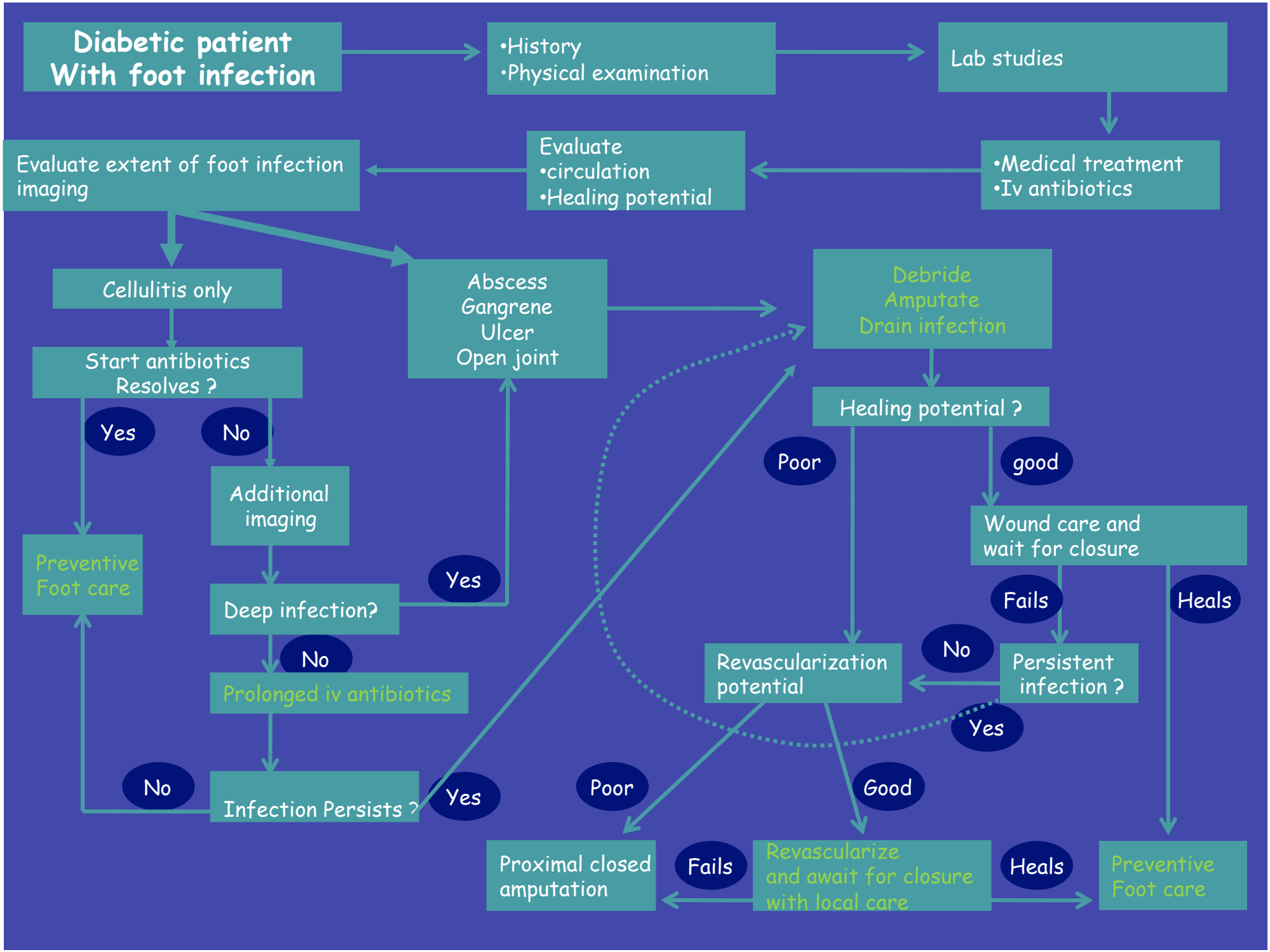
Diabetic patient
With foot infection
•History
•Physical examination
Lab studies
•Medical treatment
•Iv antibiotics
Evaluate
•circulation
•Healing potential
Evaluate extent of foot infection
imaging
Cellulitis only
Start antibiotics
Resolves ?
Yes
No
Additional
imaging
Deep infection?
Yes
No
Prolonged iv antibiotics
Infection Persists ?
Yes
No
Preventive
Foot care
Abscess
Gangrene
Ulcer
Open joint
Debride
Amputate
Drain infection
Healing potential ?
Poor
good
Wound care and
wait for closure
Fails
Heals
Persistent
infection ?
No
Yes
Revascularization
potential
Poor
Good
Proximal closed
amputation
Fails
Revascularize
and await for closure
with local care
Heals
Preventive
Foot care

Revascularization in patients with diabetic foot and aortoiliac disease

- Open reconstruction
- Endovascular procedures

Type A lesions

- Unilateral or bilateral stenoses of CIA
- Unilateral or bilateral single short (≤3 cm) stenosis of EIA

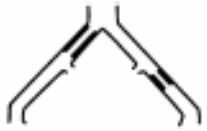

Type B lesions:

- Short (≤3cm) stenosis of infrarenal aorta
- Unilateral CIA occlusion
- Single or multiple stenosis totaling 3–10 cm involving the EIA not extending into the CFA
- Unilateral EIA occlusion not involving the origins of internal iliac or CFA

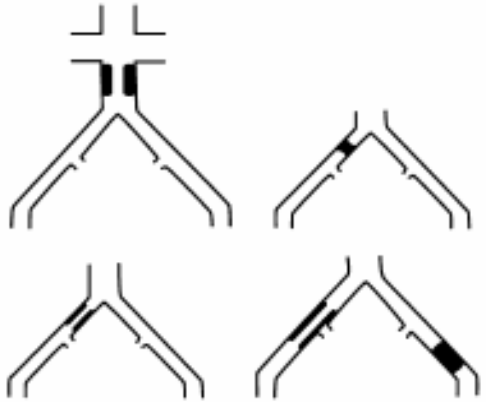

Type C lesions

- Bilateral CIA occlusions
- Bilateral EIA stenoses 3–10 cm long not extending into the CFA
- Unilateral EIA stenosis extending into the CFA
- Unilateral EIA occlusion that involves the origins of internal iliac and/or CFA
- Heavily calcified unilateral EIA occlusion with or without involvement of origins of internal iliac and/or CFA

Type D lesions

- Infra-renal aortoiliac occlusion
- Diffuse disease involving the aorta and both iliac arteries requiring treatment
- Diffuse multiple stenoses involving the unilateral CIA, EIA, and CFA
- Unilateral occlusions of both CIA and EIA
- Bilateral occlusions of EIA
- Iliac stenoses in patients with AAA requiring treatment and not amenable to endograft placement or other lesions requiring open aortic or iliac surgery

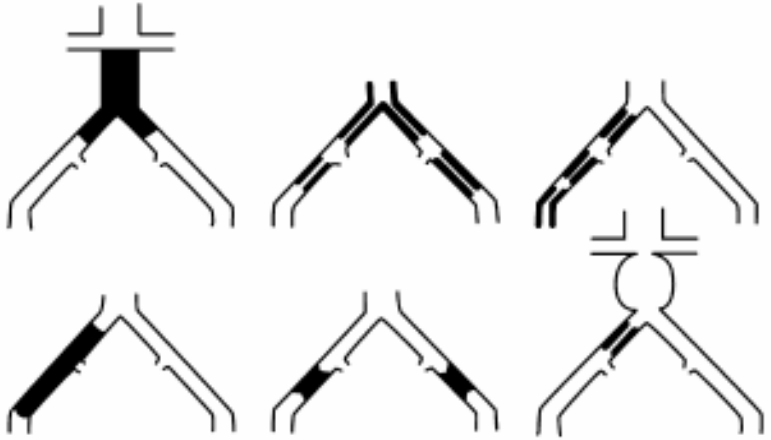

Recommendation 36. Treatment of aortoiliac lesions

- TASC A and D lesions: Endovascular therapy is the treatment of choice for type A lesions and surgery is the treatment of choice for type D lesions [C].
- TASC B and C lesions: Endovascular treatment is the preferred treatment for type B lesions and surgery is the preferred treatment for good-risk patients with type C lesions. The patient's co-morbidities, fully informed patient preference and the local operator's long-term success rates must be considered when making treatment recommendations for type B and type C lesions [C].

Open surgical reconstruction for aorto-iliac obstructive disease

- Aortoiliac endarterectomy
- Aortic graft insertion (aorto-bi-femoral Y prosthesis)
- Extranatomic (rare)
- Vollmar iliac endarterectomy

Aortoiliac endarterectomy

Dos Santos 1947 for per arteries
Wylie 1952 for aortoiliac disease

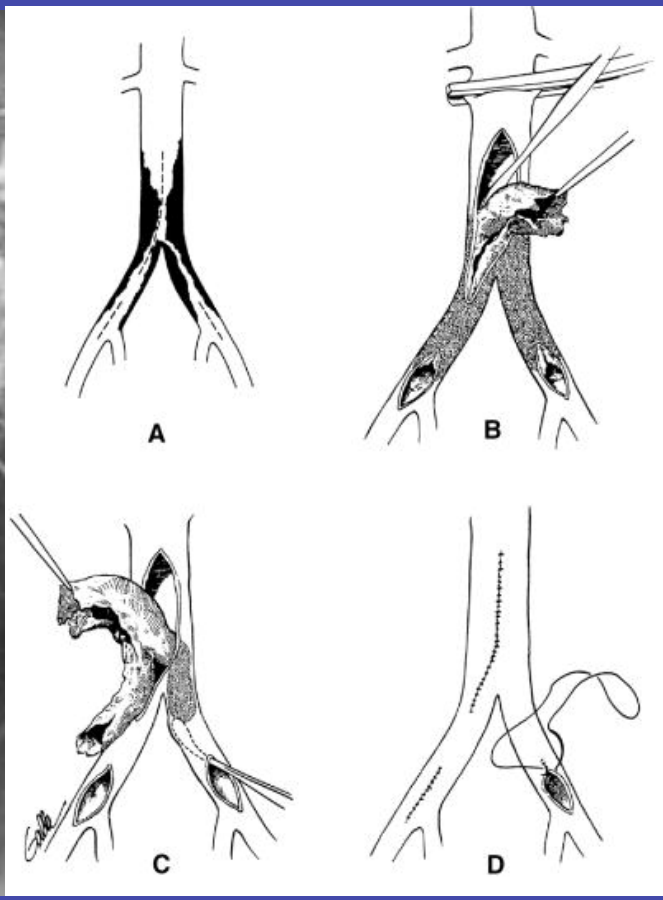

Aortic graft insertion (aorto-bi-femoral Y prosthesis)

Prox anastomosis:

End to end fashion

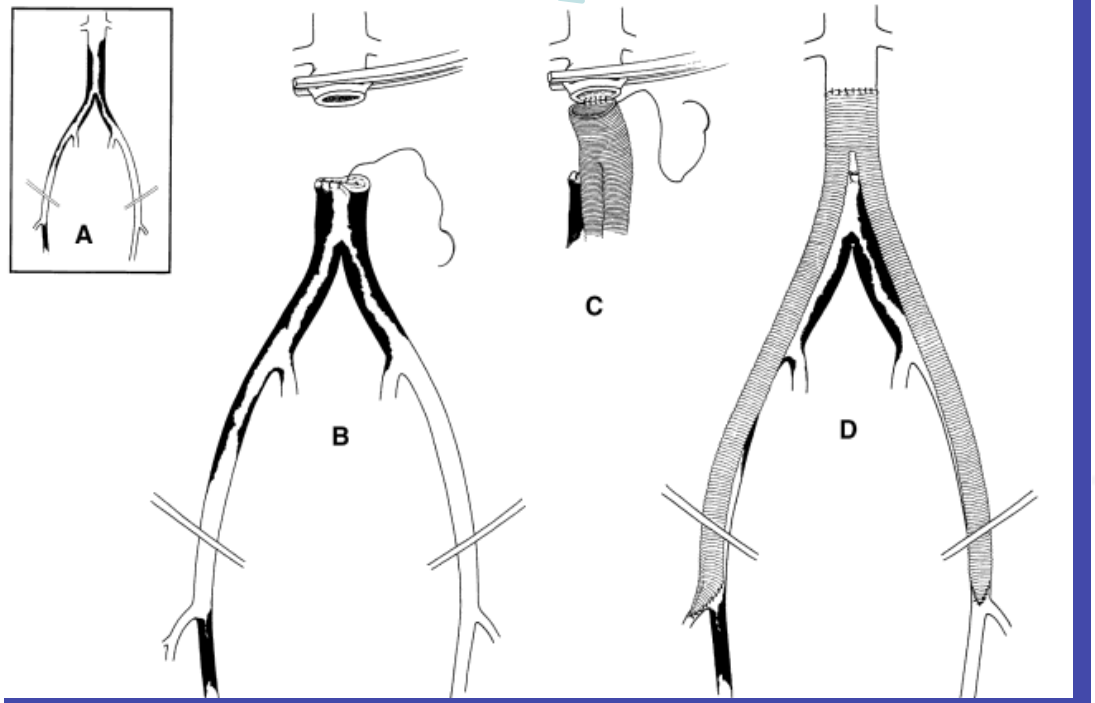

End to side fashion

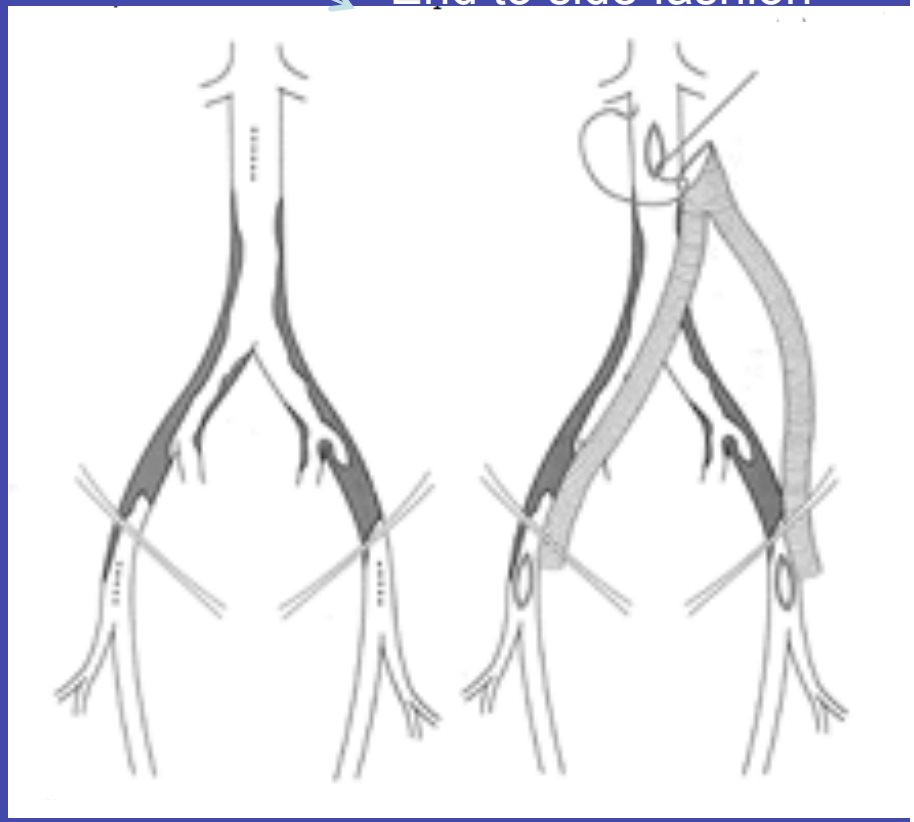

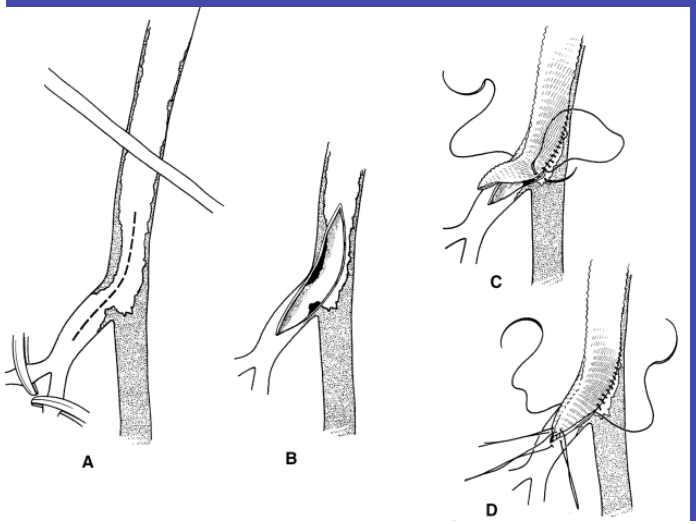

Distal anastomosis always End to side fashion

Aortic graft insertion (aorto-bi-femoral Y prosthesis)

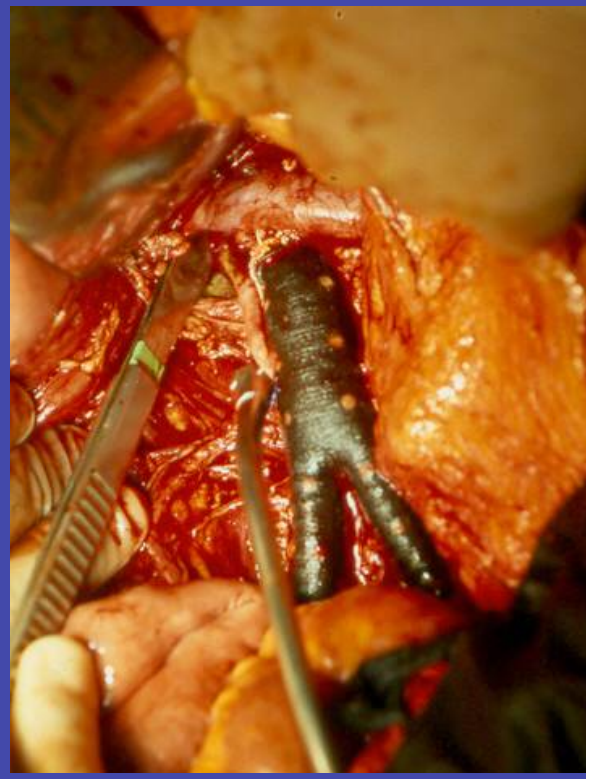

Dacron silver or

PTFE

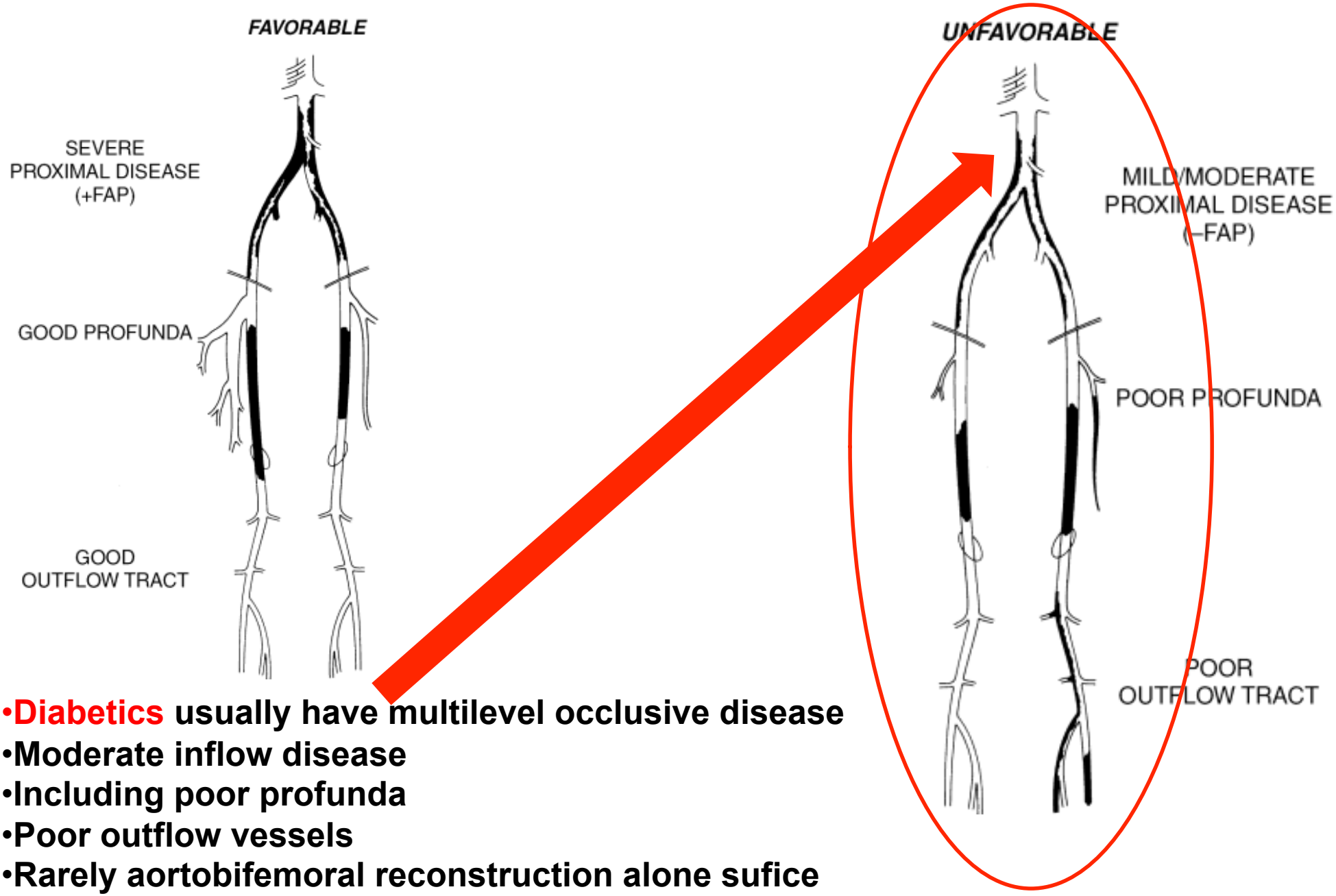

- **Diabetics usually have multilevel occlusive disease**
- **Moderate inflow disease**
- **Including poor profunda**
- **Poor outflow vessels**
- **Rarely aortobifemoral reconstruction alone sufice**
- **In diabetic infection or gangrene (stage II B complicated, III and IV meaning CLI) an adjunctive procedure is usually needed (profundoplasty, SFA stenting, by pass?, distal PTA)**

Vollmar endarterectomy

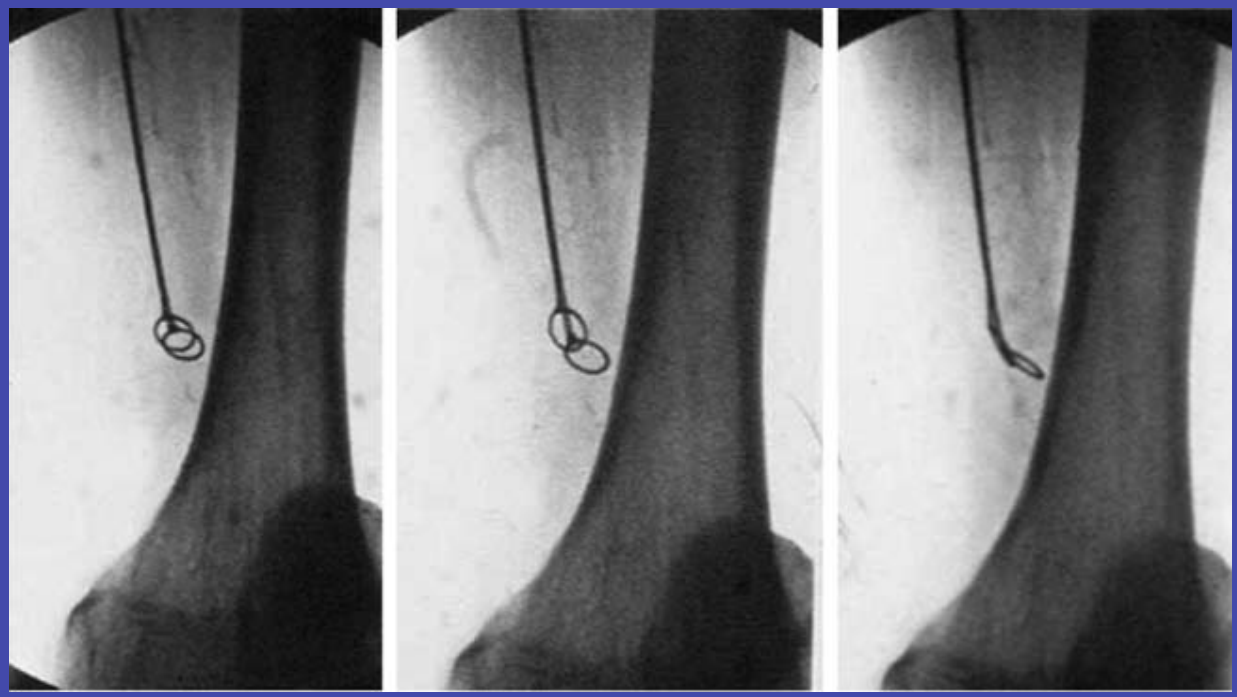

Endovascular procedures

- **Percutaneous transluminal angioplasty**
- **Stenting (BE, SE, covered)**
- **Hybrid procedures (open and endo techniques)**

PTA alone

1968 Charles Dotter

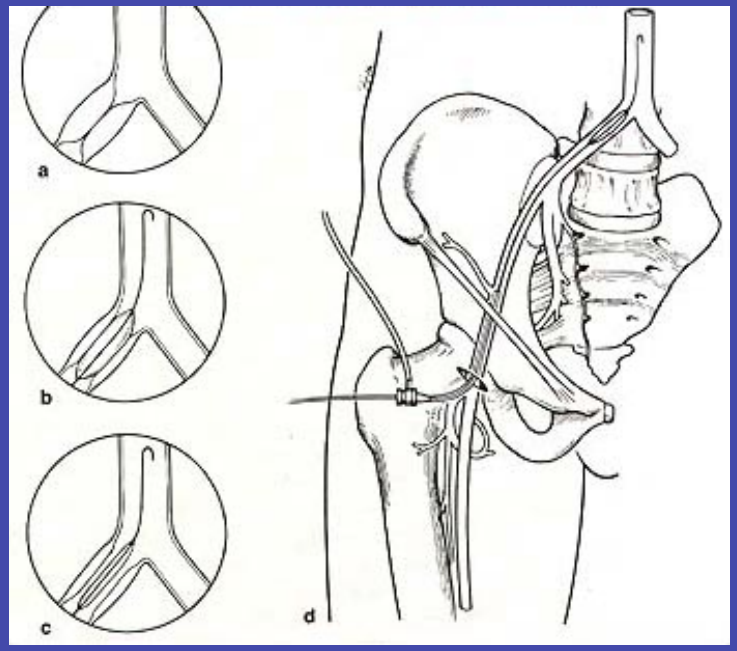

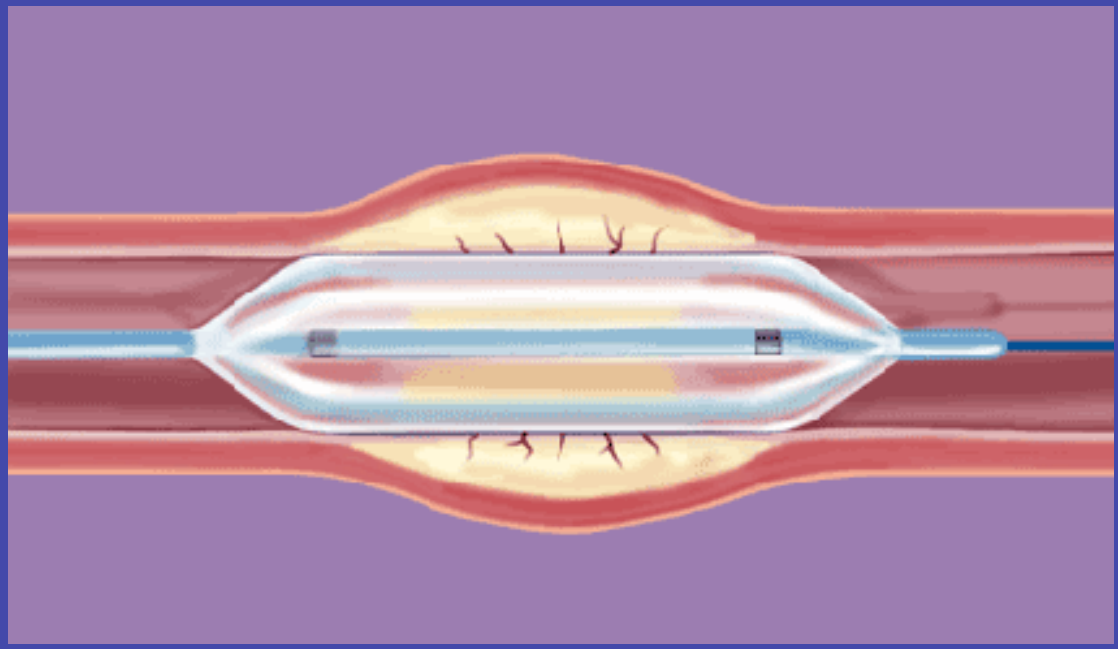



Stents

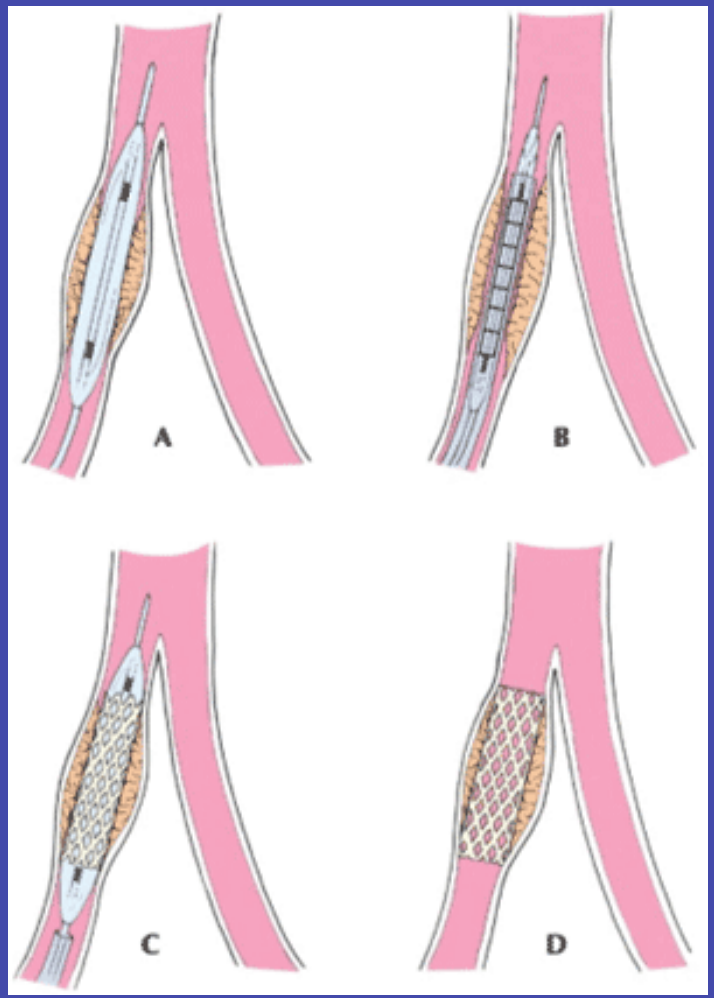

balloon expandable stents



- Metal alloy (usually Stainless steel)
- Mounted over a Pta balloon
- Reach a pre-designed diameter (atm)
- High radial force
- Low conformability in tortouosity
- Good for aortic stenosis

self expanding stents

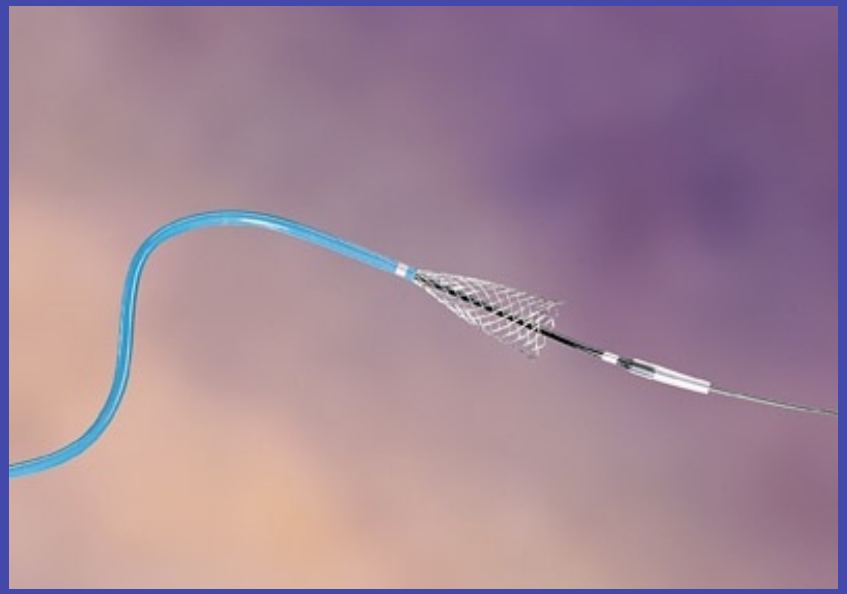



- Metal alloy usually nitinol
- Mounted inside a retrievable catheter
- Reach a pre-designed diameter
- Lw radial force
- High conformability in tortouosity
- Poor indication for aortic stenosis, good for iliacs



Covered stents







- Drug eluting stents
- Absorbable stents

Atherectomy

1.Directional atherectomy

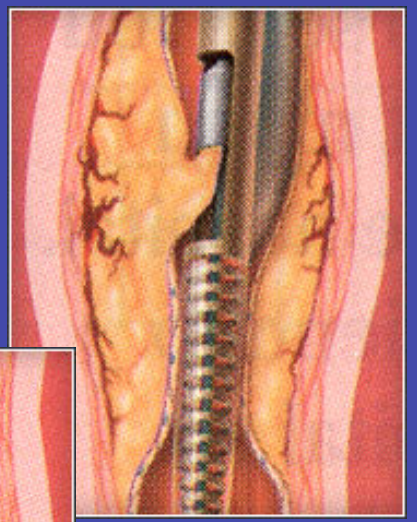

2.Rotational atherectomy

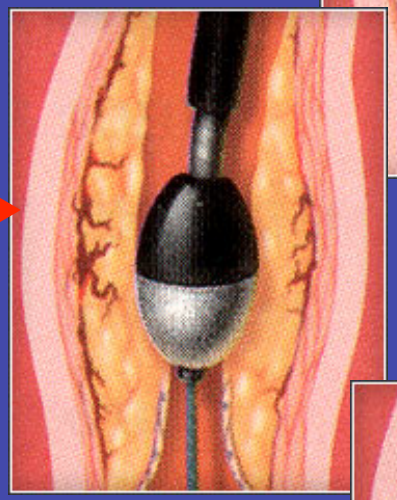

3.Excisional atherectomy

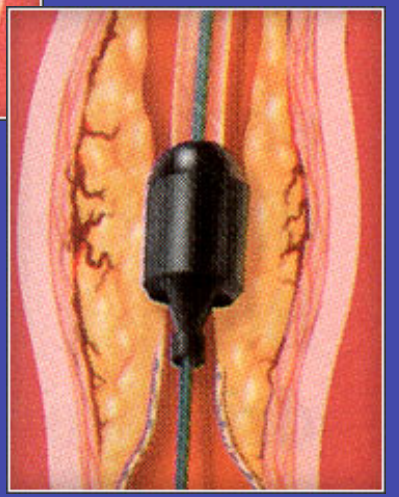

4.Excimer laser atherectomy

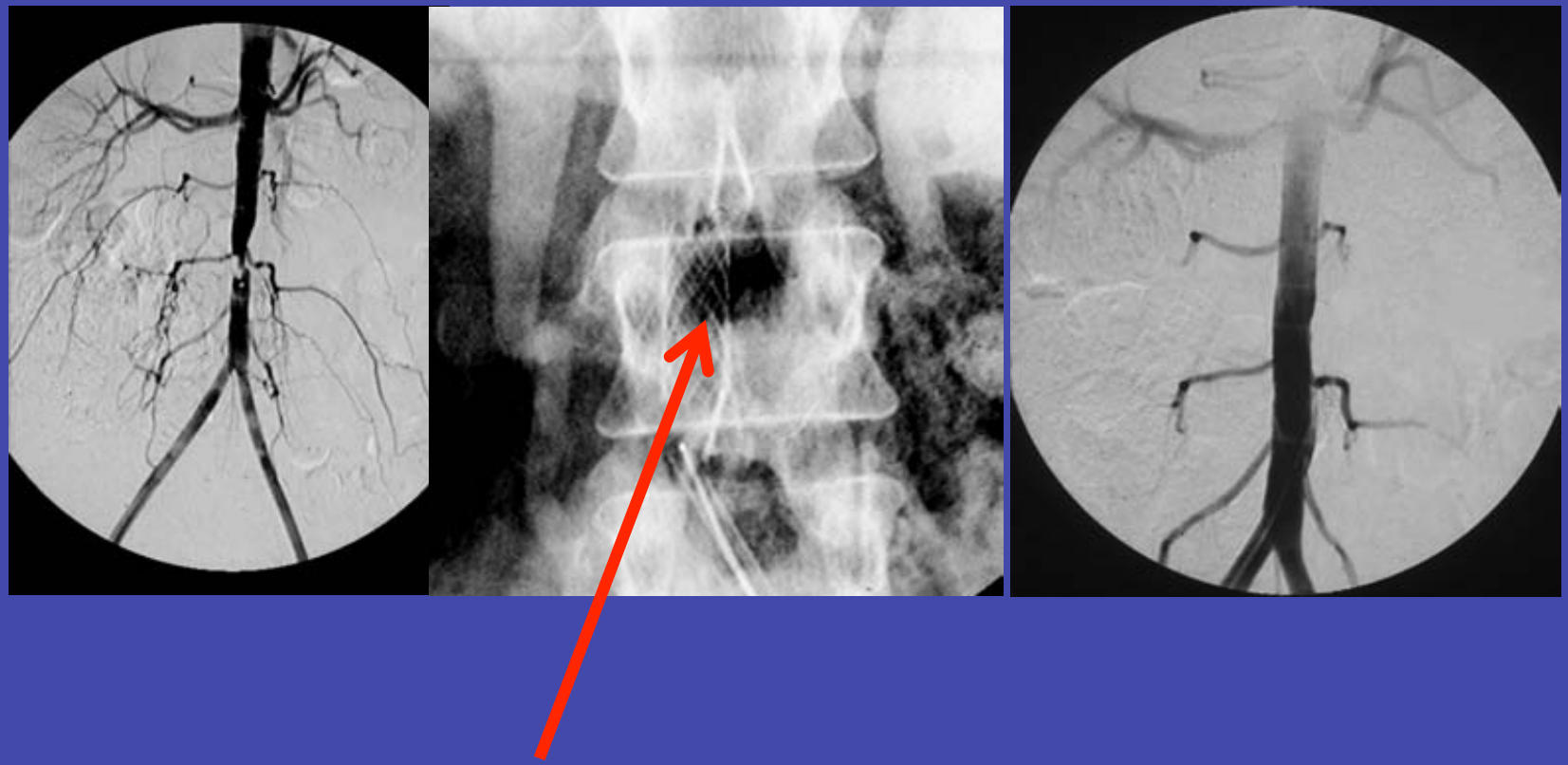

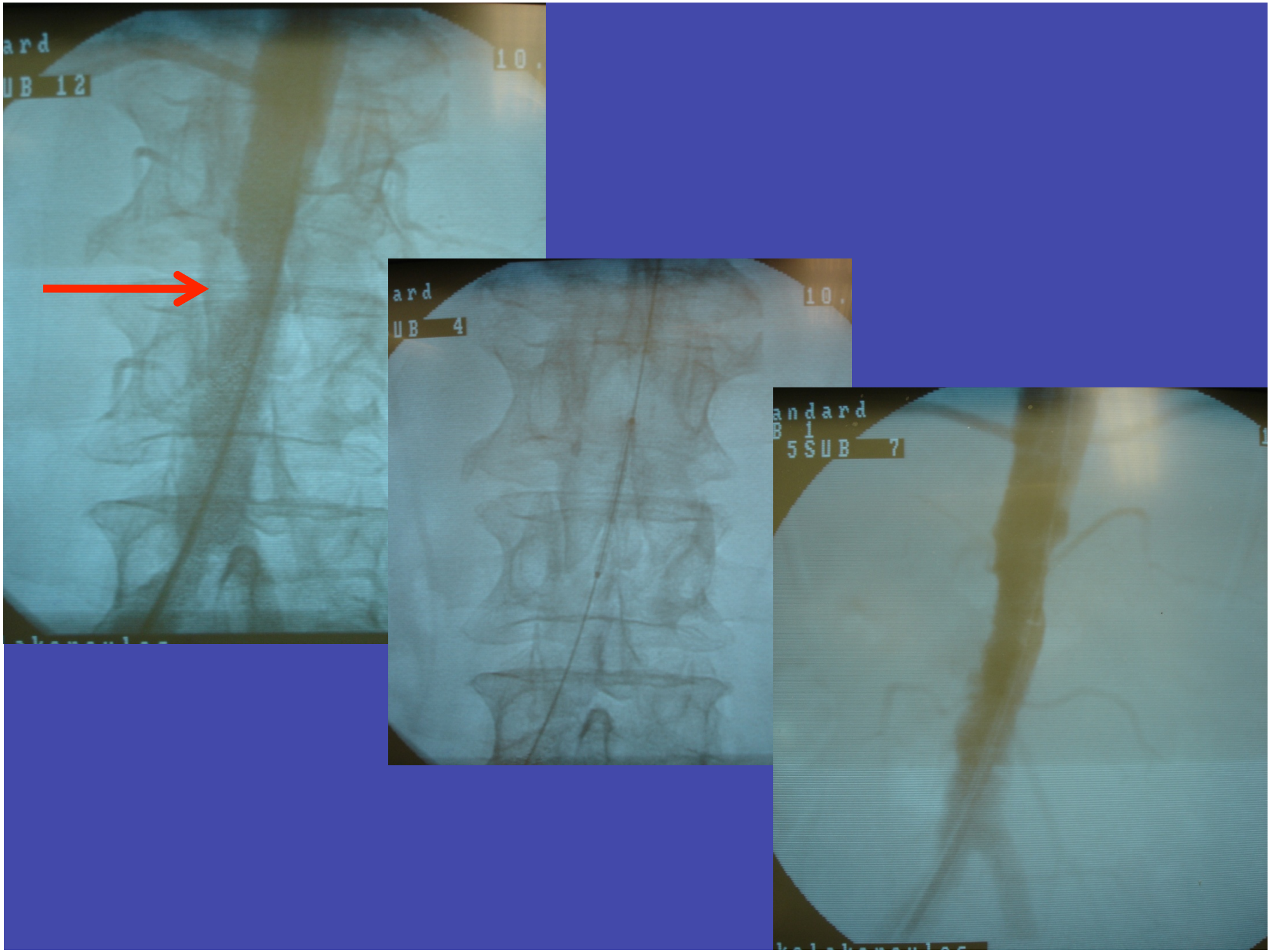
ard
UB 12
10.
ard
UB 4
10.
andard
5SUB 7

TASC A lesion

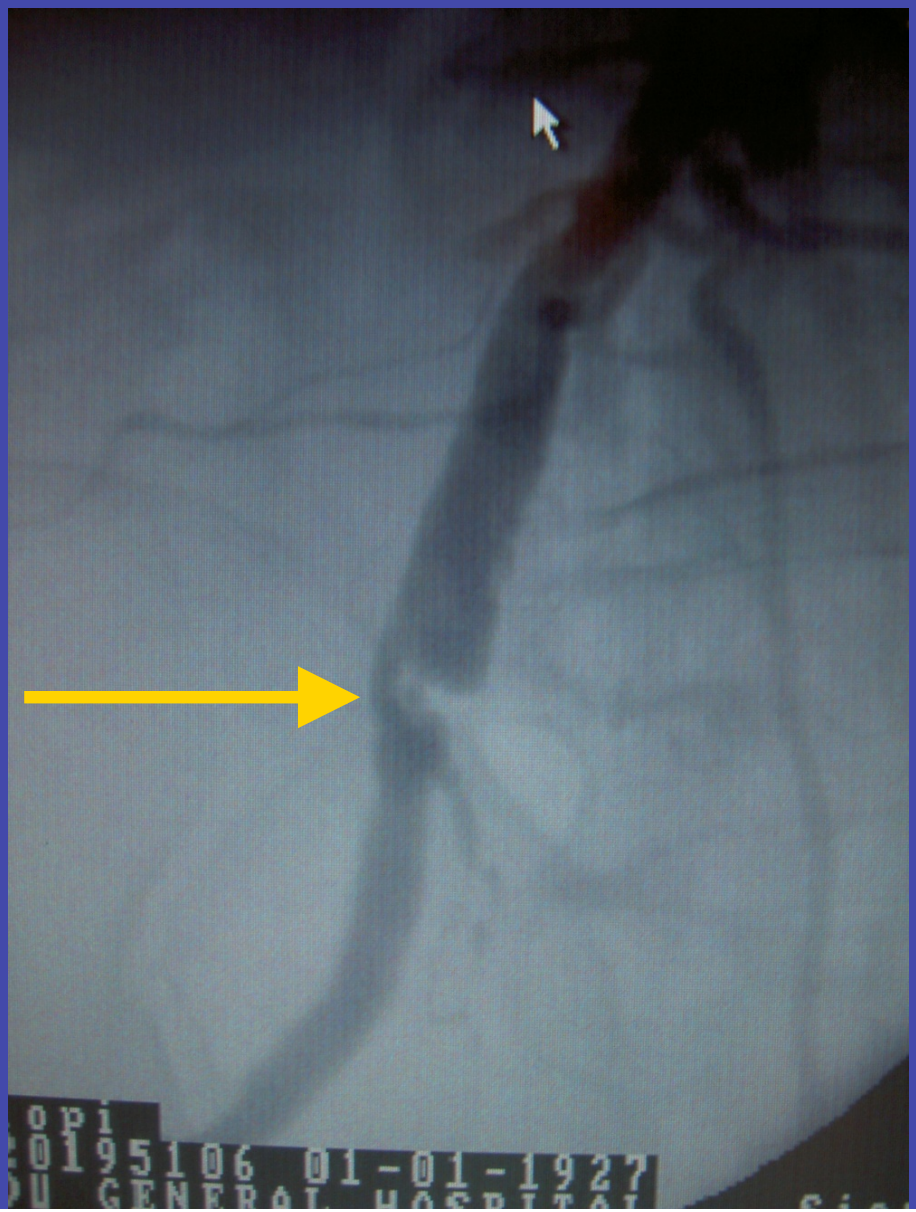

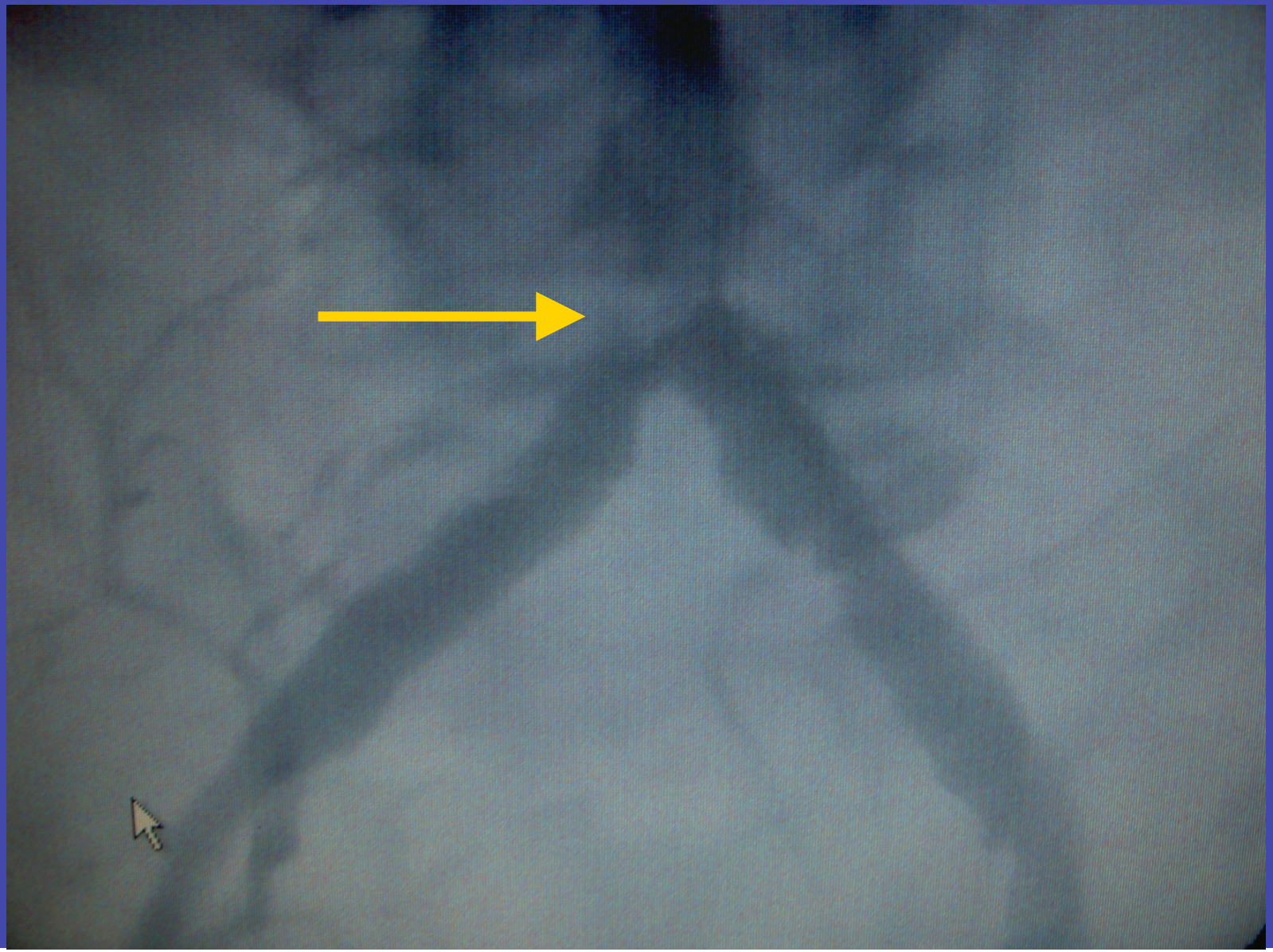

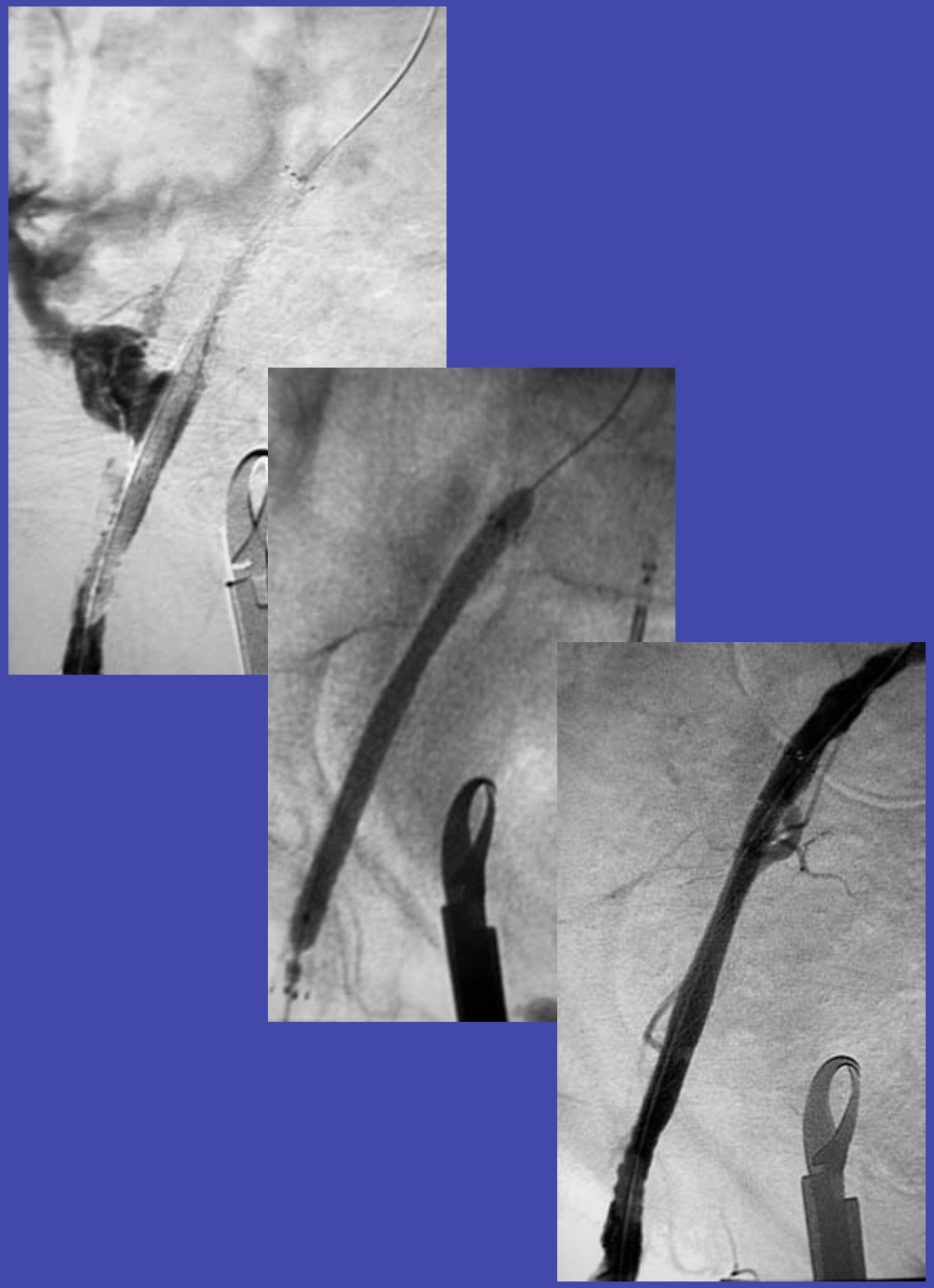

Covered stent for iliac rupture

Conclusions

- DM could cause acute catastrophic foot infection even in absence of perfusion defect.

- High index of suspicion of infection is mandatory for limb salvage.

- In Diabetic patients with aortoiliac occlusive disease before any reconstruction it is absolutely necessary to achieve absence of infection in distal foot.

- Sometimes prompt surgical intervention with debridement or even guillotine amputation is essential and life saving