

◆ SPECIAL COMMUNICATION ◆

Isolated Common Iliac Artery Aneurysms: A Revised Classification to Assist Endovascular Repair

Nikolaos Melas, MD, PhD¹; Athanasios Saratzis, MBBS, MRCS^{1,2,3}; Hannah Dixon, MBBS, MRCS²; Nikolaos Saratzis, MD, PhD¹; John Lazaridis, MD¹; Theodoros Perdikides, MD, PhD¹; and Dimitrios Kiskinis, MD¹

¹Department of General and Vascular Surgery, Papageorgiou General Hospital, Aristotle University, Thessaloniki, Greece. ²George Eliot Hospital, Nuneaton, UK. ³Russells Hall Hospital, Department of Clinical Research & Development, Dudley, UK.

Isolated common iliac artery aneurysms (CIAAs) are relatively rare; they typically progress asymptotically and are revealed incidentally, usually after they have acquired significant dimensions. Traditional open reconstruction is associated with high morbidity and mortality rates. Rupture is a common initial manifestation. Endovascular repair has been proposed as a minimally invasive alternative, associated with lower morbidity and mortality rates, even in patients at high surgical risk; some specialists have recently proposed endoluminal repair as the first-choice procedure in suitable anatomies. However, only a few sporadic attempts have been made to define the “suitable” anatomy for endovascular repair. This article proposes a classification of isolated CIAAs and provides endovascular specialists with a guide to deciding which type of repair is feasible and efficacious according to the anatomical configuration of the aneurysm.

J Endovasc Ther. 2011;18:697-715

Key words: common iliac artery, aneurysm, anatomy, classification system, endovascular repair, stent-graft, open surgery, internal iliac artery, external iliac artery, stent-graft fixation, landing zones, dilatation, treatment algorithm

PATHOPHYSIOLOGY AND NATURAL HISTORY

Iliac artery aneurysms usually coexist with abdominal aortic aneurysms (AAAs); up to 20% of AAA patients will have iliac aneurysmal disease.¹ Isolated iliac artery aneurysms without concomitant dilatation of the aorta are rare; their prevalence in the general population is estimated at 0.03%, accounting for 2% to 7%

See commentary page 716

of all intra-abdominal aneurysms and 0.6% to 7% of all aortoiliac aneurysms.²⁻⁵ Among

isolated iliac artery aneurysms, the most commonly encountered involve the common iliac artery (CIA; 70% to 90% of cases). As these CIA aneurysms (CIAAs) progress, they tend to involve the internal iliac artery (IIA) as well. On the contrary, isolated IIA aneurysms are relatively rare (10% to 30% of cases). The external iliac artery (EIA) is very seldom affected.^{4,6}

The male to female ratio for CIAAs is 5-16 to 1, and they typically appear later in life, around 65 to 75 years of age. Up to 50% of the aneurysms are bilateral.⁴⁻⁷ The pathogenesis is similar to that of AAA. The vessel wall is histologically characterized by an inflammatory infiltrate and severe proteolytic de-

The authors have no commercial, proprietary, or financial interest in any products or companies described in this article.

Corresponding author: Mr. Athanasios Saratzis, MBBS, MRCS, 122 Metchley Lane, Birmingham, UK. E-mail: a_saratzis@yahoo.gr; saratzis@doctors.net.uk

struction.^{8,9} Pseudoaneurysms, anastomotic or para-anastomotic aneurysms, and infected aneurysms are less frequent.

Isolated CIAAs usually progress asymptotically and are revealed incidentally following abdominal imaging, usually after they have grown to significant dimensions. Rupture is a common initial manifestation that also produces substantial mortality. Other complications apart from rupture include embolism, thrombosis, and compression of the adjacent structures. For aneurysms between 3 and 4 cm in diameter, the risk of rupture is 5% to 9% over 5 years.^{3,10-12} For aneurysms >4 cm, the risk of rupture is independent of the diameter, ranging from 10% to 70% over 5 years.^{6,13,14} The mean size at diagnosis is 4 to 5 cm, while the mean diameter of the ruptured aneurysms is 6 cm.¹² Mortality following rupture is as high as 25% to 57%.^{4,6}

TREATMENT

Open Surgery

Open reconstruction has been traditionally advocated for younger and fitter patients, those with multiple lesions, aneurysms >3 cm in diameter, and aneurysms that produce symptoms or have ruptured.^{6,7,15} Following an elective open procedure, the mortality is significant, most likely due to the late presentation of the pathology and the complexity of the procedure. Mortality is even higher than elective AAA repair, ranging between 5% and 11%, while for an emergency operation (following rupture), the rate ranges from 40% to 50%.^{5-7,16} Sandhu and Pipinos¹⁶ reviewed 14 series of elective open repair and reported an adjusted mortality rate of 5% (0%–13%), increasing to 28% for emergency operations (22%–60%). Santilli et al.¹⁵ evaluated 189 patients with 323 iliac artery aneurysms. They found that expansion rates were insignificant for aneurysms <3 cm (0.11 ± 0.02 cm/y) and greater ($p < 0.003$) for aneurysms ranging from 3 to 5 cm in diameter (0.26 ± 0.1 cm/y). Symptoms were noted in 6 (3.1%) patients (2 ruptures, 4 chronic pain), all of whom had aneurysms >4 cm in diameter. They concluded that aneurysms <3 cm could be followed safely by means of ultrasound surveillance on an annual basis.

Iliac artery aneurysms ranging from 3 to 3.5 cm in diameter should be followed with ultrasound scanning at 6-month intervals, whereas elective repair should be offered for aneurysms ≥ 3.5 cm in good-risk patients. Iliac artery aneurysms >5 cm in diameter require prompt repair.

Endovascular Repair

The advent of endovascular AAA repair has offered a minimally invasive alternative for treating isolated CIAAs. The procedure involves endoluminal exclusion of the pathology using a covered endoprosthesis affixed to a proximal and a distal non-aneurysmal landing zone. The initial experiences in 1995 showed a combined early and late complication rate of 18% to 27%.^{10,11,17} However, the technique has evolved substantially and has proven to be an efficacious alternative to open repair, especially for patients at high surgical risk.^{12,18-26} Sandhu and Pipinos¹⁶ reviewed 6 series of elective endoluminal iliac aneurysm repair (asymptomatic patients) and reported an adjusted mortality rate of 1% (0%–4%) and a perioperative complication rate of 20% (10%–23%). Henry et al.²⁷ reported primary and secondary patency rates are 92% and 96%, respectively. Various authors have described modified techniques in order to include shorter proximal iliac necks,^{28,29} with varying results comparable to those following open reconstruction.

Chaer et al.³⁰ were the first to directly compare open and endovascular repair. A total of 71 patients with isolated iliac aneurysms were treated (19 open vs. 52 endovascular). Seven patients presented with rupture and were offered open ($n=4$) or endovascular ($n=3$) repair. Perioperative mortality was equal in both groups for asymptomatic aneurysms (nonsignificant difference). For ruptured aneurysms, the mortality was 50% in the open group and 33% in the endovascular group (nonsignificant difference). Renal failure, myocardial infarction, wound infection, and venous thrombosis were more frequent in the open repair group, but the difference was not statistically significant. Bowel ischemia was higher in the endovascular group (nonsignificant). The need for transfusion and the length of hospital stay were higher in the open repair group ($p < 0.001$ and $p = 0.04$, respectively).

Patel et al.³¹ compared the results of 56 patients with isolated CIAAs treated with open (n=24) or endovascular repair (n=32). Among these patients, 7 had ruptured aneurysms (6 open and 1 endovascular). Thirty-day mortality rates for patients undergoing elective and emergency open repair were 6% and 17%, respectively. In the endovascular group, there was no 30-day mortality, and the median length of stay was significantly lower ($p<0.01$). There was no midterm aneurysm-related mortality in either group. Primary patency rates were similar at 5 years ($p=0.07$).

EXISTING CLASSIFICATIONS

Some authors have recently proposed endovascular repair as the first-choice procedure for suitable iliac anatomies,³² given the minimal invasiveness of the technique and encouraging early results. However, only a few attempts have been made to define the "suitable" anatomy for endovascular CIAA repair. The authors classified these aneurysms specifically for endovascular intervention^{16,33,34} but failed to include all possible anatomical configurations.

Fahrni et al.³⁴ proposed a classification to aid endovascular exclusion based on their experience with 19 patients. Depending on the configuration of the proximal iliac neck and whether the disease is uni- or bilateral, isolated CIAAs may be treated with a tubular (type Ia) or a bifurcated stent-graft (type Ib) and IIA embolization, if necessary. They also pointed out that neck anatomy is critical in determining the options for IIA aneurysm repair: these options include the deployment of a tubular stent-graft (CIA to EIA) followed by IIA branch embolization (type IIa), coil embolization of the afferent and efferent internal iliac vessels (type IIb), and IIA aneurysm packing (type IIc). This was the first attempt to systematically classify iliac aneurysms in order to assist decision making for a subsequent endovascular repair.

Sandhu and Pipinos¹⁶ introduced another classification, taking the morphology of the IIAs into account as well. Type A included isolated CIAAs with proximal and distal necks of "adequate" length for open or endovascular repair. Type B referred to isolated CIAAs

with "adequate" proximal neck and aneurysmal disease extending to the CIA bifurcation. Type C included isolated CIAAs with "adequate" proximal necks and aneurysmal disease extending to the CIA bifurcation (involving the IIAs). Isolated IIA aneurysms not involving the CIA were classified as type D. Type E included CIA aneurysms with "inadequate" proximal necks (aneurysm involving the CIA ostium or aortic bifurcation), or bilateral CIA aneurysms, or combined CIAAs and AAA. However, various types of aneurysmal disease of the iliac axis were not included in the classification. Moreover, they proposed that proximal iliac necks >1 cm long and with minimal mural thrombus or calcification be considered adequate for proximal attachment and fixation of an endoluminal prosthesis in the iliac artery; however, such a short landing zone may prove unsafe. Furthermore, the proposed classification did not take the diameter and contour of the iliac neck into account.

Sakamoto et al.³⁵ in 2005 published a more thorough classification. They proposed 5 distinct types (I-V) of iliac aneurysms based on anatomical features. Type I included IIA aneurysms distal (>2 cm) to the origin of the IIA, allowing proximal embolization, whereas type II included IIA aneurysms unsuitable for embolization because the aneurysmal segment was proximal to the origin of the IIA (<2 cm). Type III were CIAAs sufficiently distal (>2 cm) to the aortic bifurcation to allow deployment of a straight stent-graft, whereas type IV referred to CIAAs that were not sufficiently distal (<2 cm) to the bifurcation to allow the deployment of such a device. Type V included CIA or IIA aneurysm that developed after AAA repair with a bifurcated graft.

OPTIMAL LANDING ZONE IN ANEURYSMAL ILIAC ARTERIES

Based on previous experience from endovascular repair of AAA and descending thoracic aortic aneurysms, a "suitable iliac landing zone" (proximal or distal) would have an appropriate length and diameter of nondiseased vessel to accommodate the endoluminal device,³⁶ minimizing the risk of migration or endoleak. The length, diameter, shape, and

angulation of the landing zone play significant roles in decision making prior to endovascular repair and significantly impact the postoperative outcome.³⁶⁻⁴⁰

Adequate Diameters and Lengths for Endovascular Repair

There is a serious lack of studies evaluating the adequate diameter or length of the vessel that could act as an attachment (landing) zone in endovascular repair of isolated iliac aneurysms. As a result, conclusions have to be drawn from studies investigating the characteristics of the optimal distal landing zone in AAA and aortoiliac aneurysm repair.

Hassen-Khodja et al.⁴¹ investigated the fate of the CIA in 147 patients following the placement of a tubular aortic graft (open reconstruction) for the elective treatment of infrarenal AAAs. Patients were divided into 3 groups: in group A (40.1%) both CIAs were of normal diameter (<12 mm), in group B (36.1%) at least 1 CIA was ectatic (diameter between 12 and 18 mm), and in group C (23.8%) at least 1 CIA was aneurysmal (diameter >18 mm). They showed that CIAs <12 mm in diameter increased by a mean of 1 mm over 5.5 years, CIAs between 12 and 18 mm in diameter increased by a mean of 1.7 mm over 5 years, and CIAs between 18 and 25 mm in diameter increased by 2.3 mm over the same period. They concluded that treating a dilated CIA (during AAA repair) is justified even for moderate CIA dilatation (<18 mm). Other authors also found similar enlargement rates for untreated ectatic CIAs when repairing AAAs with tubular grafts.⁴²⁻⁴⁸ As a result, it is reasonable to suggest that a moderately dilated iliac artery would not make an appropriate landing zone due to the risk of future dilatation. However, the aforementioned studies included patients treated with aortic tubular grafts, where the iliac arteries were directly exposed to high blood flow forces. Iliac arteries acting as landing zones in endovascular repair of iliac aneurysmal disease are covered by an endograft and will not be directly subjected to such high expansile forces.

Kritpracha et al.⁴⁹ proposed the "bell-bottom" technique (aortic extension cuffs or large iliac

limbs on an aortoiliac stent-graft) to avoid potential ischemic complications of IIA overstenting. They treated aneurysmal CIAs (aortoiliac aneurysms) having a mean diameter of 19 mm, achieving favorable short-term results. The maximal CIA diameter in this series was 24 mm. On the contrary, Clarke et al.⁵⁰ utilized a different technique for treating a similar case. McDonnell et al.⁵¹ found that using ectatic CIAs (16-22 mm) as a distal landing zone resulted in 7% type Ib (distal) endoleak during aortoiliac aneurysm repair. They concluded that iliac arteries >16 mm in diameter should be treated with a flared graft, and 22 mm was the maximal acceptable diameter. Malagari et al.⁵² and Karch et al.⁵³ also recommended implantation of flared iliac limbs in cases of CIA ectasia and found that most CIAs do not increase in diameter. Hinchliffe et al.⁵⁴ proposed direct suturing of an aortoiliac stent-graft to the CIA bifurcation via an extraperitoneal approach (hybrid procedure) when the CIA is >22 mm in diameter and the distal neck is inadequate for device fixation. In the case of CIAs measuring <22 mm in diameter, they advocated using the bell-bottom technique. The Table summarizes the results of studies investigating the maximum appropriate iliac artery diameter that can safely serve as a landing zone for endovascular repair.

In the classification by Sandhu and Pipinos,¹⁶ the authors proposed that proximal iliac necks that are >1 cm long and have minimal mural thrombus or calcification are adequate for proximal attachment and fixation of endoluminal prostheses. Sakamoto et al.³⁵ concluded that a 2-cm non-aneurysmal segment of the CIA below the aortic bifurcation allows safe deployment of a straight stent-graft. Based on these and other results,^{16,35,41-54} the proximal CIA landing zone should have a length >20 mm and a diameter <18 mm to be considered as "suitable" for endovascular repair (Fig. 1). A shorter or wider proximal neck provides inadequate attachment. In the event of an insufficient proximal neck, the proximal landing zone for isolated CIAA endovascular exclusion should be relocated proximally, over a healthy aortic segment using an aortomonoiliac or bifurcated stent-graft. Similarly, the distal CIA landing zone

TABLE
Studies Investigating the Maximum Safe Diameter of an Iliac Landing Zone in Endovascular Repair of Iliac Aneurysms

	CIA Diameter, mm	Mean Follow-up, mo	Complications
Kritpracha ⁴⁹	<24 (mean 19)	8	No CIA dilatation or delayed type I endoleak. Diameters of the treated CIAs remained unchanged.
McDonnell ⁵¹	<22 (mean 19.7)	30.1 ± 8.3	3% aneurysm-related death. 7% endoleak type Ib. 2% endoleak type Ia. 10% re-intervention rate.
Malagari ⁵²	<28 (mean 18.2)	33.6	No CIA dilatation in 84%. Failure of distal attachment in 6.2%.
Karch ⁵³	<20 (mean 18)	14 (range 6-24)	CIA diameter stable in 61%, increased by 1 mm in 22%, and decreased by 1 mm in 17%.
Hinchliffe ⁵⁴	<22	Short term - unspecified	No endoleaks, ruptures, migration. Unspecified.

CIA: common iliac artery.

should have a length >20 mm and a diameter <20 mm to be considered a "suitable" distal landing zone (Fig. 1). If these requisites are not met, the distal landing zone should be relocat-

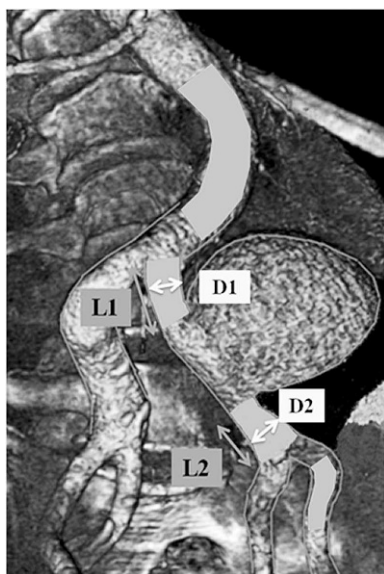


Figure 1 ♦ Defining the "suitable" iliac landing zone. L1: length of proximal CIA landing zone. D1: diameter of proximal CIA landing zone. L2: length of distal CIA landing zone. D2: diameter of distal CIA landing zone. If L1 >20 mm and D1 <18 mm, this is considered a "suitable" proximal CIA landing zone for endovascular repair. Similarly, if L2 >20 mm and D2 <20 mm, this is a "suitable" distal CIA landing zone. When the internal iliac artery is used as a distal landing zone, there should be >20 mm of non-aneurysmal vessel with a diameter <15 mm.

ed distally at the level of the EIA, sacrificing antegrade hypogastric perfusion. Adjunctive IIA embolization is sometimes mandatory. If the proximal and distal landing zones are contoured (tapered, reverse tapered, or bulged) or there is excessive thrombus or calcification present, the landing zone should be considered unsuitable.

REVISED CLASSIFICATION

Based upon the aforementioned definition of a "suitable" landing zone at the iliac axis, 5 basic types of isolated CIAAs can be defined according to their anatomical configuration (Fig. 2):

- ♦ Type A: suitable proximal and distal CIA landing zones are present.
- ♦ Type B: a suitable proximal landing zone is present, but the configuration of the distal landing zone is unsuitable for endovascular repair. This category can be subdivided into B1, when the aneurysmal CIAA does not extend into the IIA (there is at least 20 mm of non-aneurysmal tissue within the IIA with a diameter <15 mm) and B2, when the aneurysmal CIA extends into the IIA, but there is insufficient (<20 mm) non-aneurysmal IIA <15 mm in diameter.
- ♦ Type C: a suitable distal landing zone is present, but the proximal landing zone is unsuitable.
- ♦ Type D: both distal and proximal landing zones are not suitable for endovascular

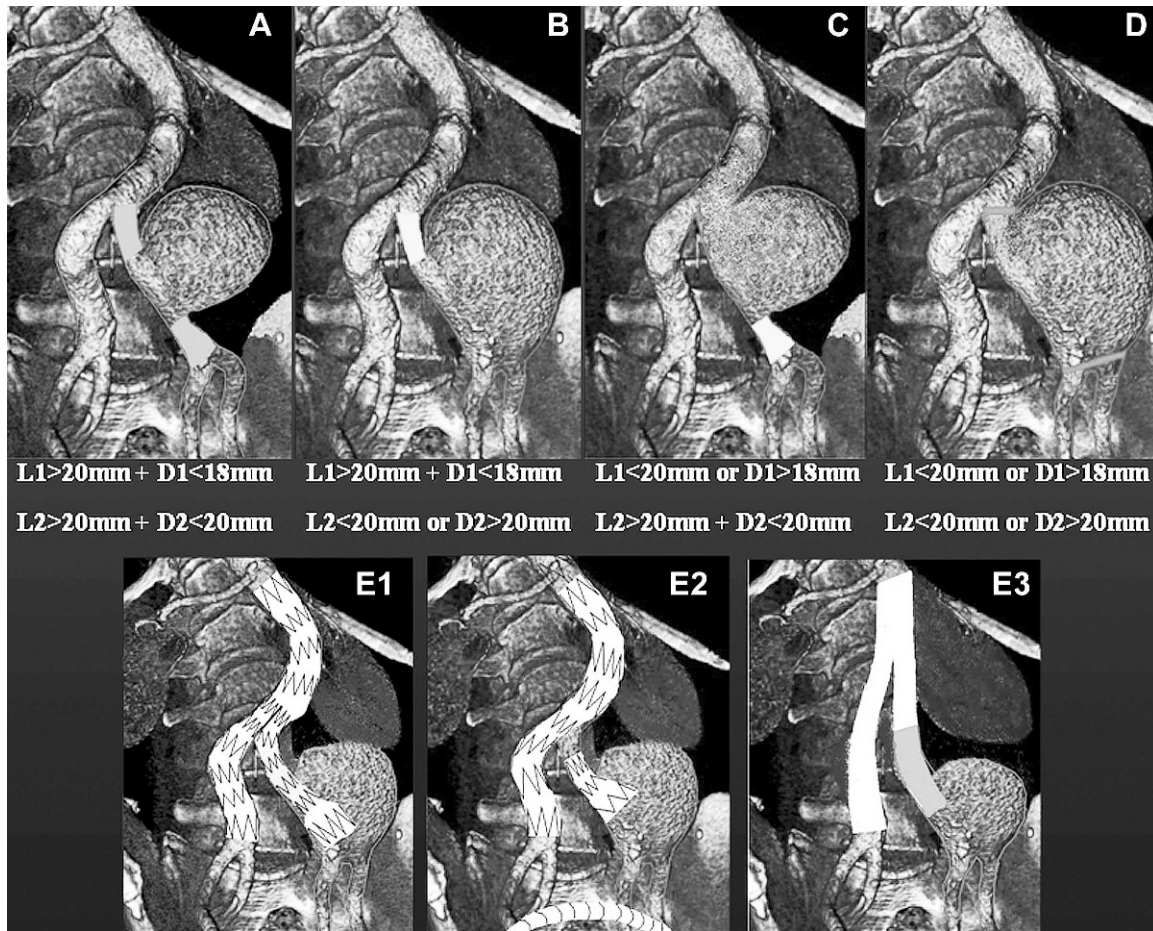


Figure 2 ♦ Classification of isolated CIA aneurysms. According to the suitability of the proximal and distal landing zones, the isolated CIA aneurysms can be classified into 5 categories (A-E). Type A: suitable proximal and distal CIA landing zones. Type B: there is a suitable proximal CIA landing zone, but not one distally; this is divided in B1 when the CIA aneurysm does not extend to the IIA and B2 when the aneurysm extends to the IIA (not illustrated). Type C: there is a suitable distal CIA landing zone, not one proximally. Type D: unsuitable CIA landing zones proximally and distally; this is divided in D1 when the CIA aneurysm does not extend to the IIA and D2 when the aneurysm extends to the IIA (not illustrated). Type E: CIA aneurysms secondary to previous open or endovascular repair. Type E1: CIA aneurysm after previous bifurcated endograft for AAA. Type E2: CIA aneurysm after previous aortomonoiliac endografting for AAA, and the dilatation is relative to the occluder. Type E3 “para-anastomotic” iliac aneurysm after previous open aortic reconstruction.

repair. This category, like category B, can be subdivided. Category D1 applies when the CIAA does not extend to the IIA (there is at least 20 mm of non-aneurysmal tissue within the IIA with a diameter <15 mm), and D2 indicates that the CIAA extends to the IIA, but there is insufficient (<20 mm) non-aneurysmal IIA <15 mm in diameter.

- ♦ Type E: CIAAs that present secondary to previous open or endovascular AAA repair

(Fig. 2). E1 includes CIAAs developing after endovascular placement of a bifurcated endograft or aortomonoiliac device with the dilatation at the ipsilateral iliac axis; E2 involves CIAAs after endovascular placement of an aortomonoiliac device, and the dilatation seen at the iliac axis is ipsilateral to the occluder; and type E3 involves “para-anastomotic” iliac aneurysms after previous open reconstruction of an AAA

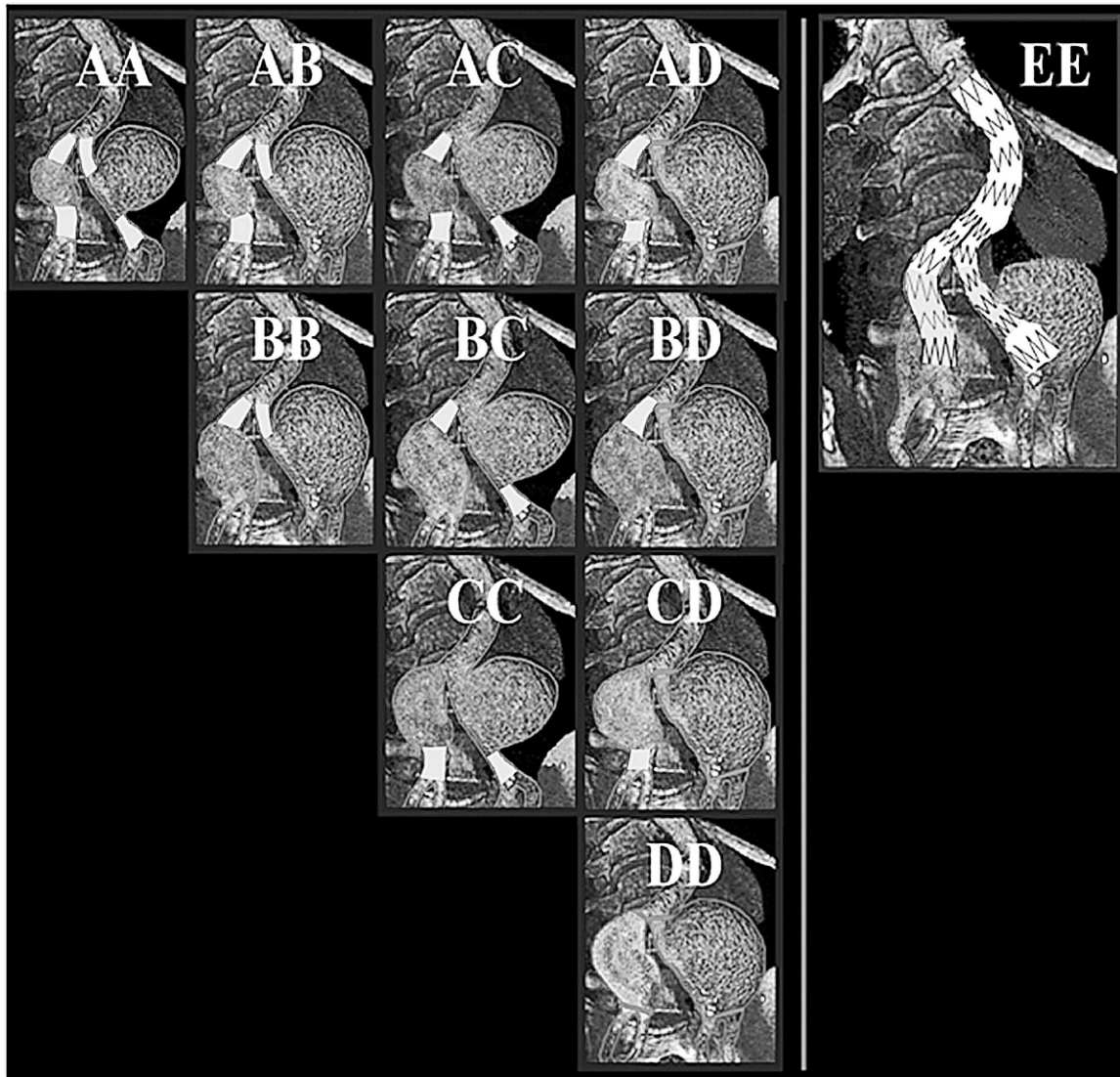


Figure 3 ♦ Classification of bilateral isolated CIA aneurysms. The right and left iliac axes are represented with letters corresponding to each aneurysm. First letter (A-D) represents the anatomy of the right axis and the second the anatomy of the left axis. Thus, E1E1 represents bilateral aneurysmal dilatation of the CIAs after previous bifurcated endograft for AAA (illustrated as EE). E3E3 represents “para-anastomotic” aneurysms after previous open aortic reconstruction. E1E2 represents secondary bilateral iliac aneurysms after aortomonoiliac repair (not illustrated).

with a bifurcated aortoiliac graft. Distal landing zones suitable for endovascular repair would not likely be found in conjunction with iliac aneurysms secondary to AAA repair; therefore, no further subdivisions have been made.

Bilateral isolated CIAAs are also frequent; therefore, we have attempted to create a classification system that would also describe

bilateral isolated CIAAs. The proposed definitions of suitable landing zones and the aforementioned A-E categories apply here as well. The left and the right iliac axes are simultaneously represented with the proposed letters, with the first letter (A-D) representing the anatomy of the right iliac artery and the second letter (A-D) representing the anatomy of the left iliac artery (Fig. 3). Moreover, in the event of concomitant IIA aneurysms in cate-

gory B or D, these could be further divided in B1 or D1 when the CIAA does not extend to the IIA and B2 or D2 when the CIAA extends up to the IIA.

IIA Occlusion

When repairing an iliac aneurysm with an endovascular device, occlusion of the IIA could impair pelvic flow. Unilateral IIA occlusion usually produces no symptoms but may occasionally cause transient buttock claudication, impotence, and colonic or spinal cord ischemia at composite rates up to 39%.⁵⁵⁻⁵⁸ Bilateral interruption of previously patent IIAs can produce significant ischemic complications more often and result in severe morbidity and mortality.⁵⁵⁻⁵⁸ Following open aortoiliac reconstruction, there are numerous reports of impotence, buttock claudication, anorectal necrosis, and even paralysis of the lower extremities as a result of acute ligation or thrombosis of a patent IIA.⁵⁹⁻⁶¹ Parodi et al.,⁶² May et al.,⁶³ and Marin et al.¹⁷ reported that complex aortoiliac aneurysms could be easily treated with aortomonoiliac stent-grafts and an adjunctive femorofemoral crossover bypass. In these early studies, the adverse effect on pelvic circulation when one or both IIAs were sacrificed did not significantly impact the early outcome. Data from conventional open operations show a low incidence of pelvic ischemic sequelae after aortoiliac reconstruction for aneurysmal or occlusive disease^{64,65} when sacrificing the IIA. Other series with aortomonoiliac devices for aortoiliac aneurysms^{66,67} or isolated CIAAs^{28,29} also reported low morbidity associated with unilateral IIA occlusion.

Iliopoulos et al.⁶⁸ conducted a study measuring intraluminal IIA pressure and its variations after intermittent clamping of the pelvic branches in 10 patients undergoing either aortobi-iliac or aortobifemoral bypass grafting for aneurysmal or occlusive disease. The findings suggested that ascending branches from the ipsilateral EIA and deep femoral system provide a more significant collateral pathway to the region of the occluded IIA than the contralateral patent IIA. The authors concluded that it is important to preserve or even reconstruct diseased

vessels in the EIA-deep femoral system ipsilateral to an occluded IIA to minimize the risks of pelvic ischemia.

Mehta et al.⁶⁹ analyzed 154 patients with either unilateral (n=134) or bilateral (n=20) IIA occlusions during endovascular (n=107) or open repair (n=47). They found no cases of buttock necrosis, ischemic colitis requiring laparotomy, or death when one or both IIAs were occluded. Persistent buttock claudication occurred after 12% of the unilateral and 11% of the bilateral IIA occlusions. Impotence occurred in 9% of the unilateral and 13% of the bilateral occlusions. Minor neurological deficits of the lower extremity were observed in 1.5% of the patients with unilateral IIA occlusion. Other factors, such as shock, distal embolization, or failure to preserve collateral branches from the external iliac and femoral arteries, may also contribute to subsequent morbidity. Engelke et al.⁷⁰ concluded that unilateral IIA coverage might cause benign symptoms with a 25% incidence of buttock claudication, but bilateral IIA occlusion should generally be avoided and is recommended only in patients who are considered unfit for aortic surgery.

Kritpracha et al.⁷¹ reviewed the literature to specify the incidence of pelvic ischemia consequent to uni- or bilateral IIA coverage. They found that unilateral IIA coverage resulted in an average of 34% pelvic ischemic complications: 81% buttock claudication, 10% sexual dysfunction, 8% colonic ischemia, and 3% minor neurological deficit or persistent sacral ulcer. Following bilateral occlusion, ischemic sequelae were found in 43% of patients. As a result, bilateral IIA occlusion should generally be avoided. Unilateral IIA occlusion will not produce significant symptoms in the majority of patients, but extra care is mandatory to avoid occlusion of the vessel in patients at high risk for ischemia, such as arteriopathies.

Stent-graft coverage of the IIA orifice alone can suffice if the device will completely seal the orifice. The latter should be verified on an intraoperative angiogram. Most interventionalists prefer coil embolization of the IIA.⁷²⁻⁷⁷ However, Farahmand et al.⁷⁸ proposed that coil embolization can be avoided in suitable anatomies. They investigated 101 IIA occlusions during aortoiliac aneurysm repair (endo-

vascular); coil embolization was used in 75% of these and 25% of the IIAs were simply covered by the limb of the stent-graft. Buttock claudication was apparent in 42% of patients within the coil group and in 8% within the other group. The rates of postoperative sexual dysfunction and type II endoleak were equal among groups. They hypothesized that the coverage of the IIA with a stent-graft causes an occlusion of the artery in its proximal segment, allowing collateral network formation in distal segments of the artery. In contrast, embolization may cause the formation of microthrombi that tend to disseminate, leading to embolic occlusion of secondary branches and collaterals. Wyers et al.⁷⁹ also supported this finding. They found that simple overstenting of the IIA without coil deployment effectively excluded the CIA aneurysm in every case and was associated with a low incidence of complications compared with coil embolization. With detailed preoperative imaging and patient selection, IIA coil embolization may not be necessary in as many as two thirds of patients. Similar findings were published by Mell et al.⁸⁰ and Kritpracha et al.⁷¹ Rajasinghe et al.⁸¹ reported a novel technique using a large caliber endograft that occludes the IIA orifice prior to deploying the stent-graft, which lands distally into the EIA. Other investigators favor the use of a vascular plug instead of coils or overstenting.^{82,83}

OPTIONS FOR ENDOVASCULAR REPAIR OF ISOLATED CIAAS

Covered Stents and Iliac Limbs or Aortomonoiliac Endografts

A straight covered stent or an iliac limb of an aortic graft can be deployed directly at the site of an iliac aneurysm. Proximally, it is fixed on a healthy segment of the CIA and distally onto the CIA or EIA. Aortomonoiliac devices have long been used to repair complex aortoiliac aneurysms.^{62,63} Marin et al.¹⁷ and Cardon et al.¹⁰ used aortomonoiliac grafts to treat isolated iliac aneurysms as well. The safety and durability of the procedure have been proven in several case series.^{22-29,84-89} Most of the initial reports did not precisely define the desirable length or diameter of the

landing zones. Boules et al.⁹⁰ concluded that the procedure has similar results to that of endovascular AAA repair.

In the majority of patients, when using the aortomonoiliac configuration to treat an isolated CIAA, the ipsilateral IIA will have to be occluded, as the CIA is aneurysmal proximal to the IIA orifice. Extension of the endoprosthesis to the EIA is therefore mandatory. Adjacent IIA occlusion is generally advised to avoid type II endoleak; either coils or plugs may be used as discussed previously.

A significant advantage of repairing an iliac aneurysm with a covered stent or iliac limb deployment is the fact that the procedure can be performed percutaneously under local anesthesia.^{91,92} However, there is restricted availability of endografts with regard to dimensions. The tapered limbs of the available endografts proximally measure <16 mm because they are designed to accommodate the corresponding docking zones of the endografts. That means that proximal iliac landing zones between 14 and 18 mm cannot be treated with a single limb. Alternatively, tubular iliac extensions come in larger diameters up to 28 mm, but when the distal landing zone is inside the EIA, the oversizing would be very significant. In some cases, using the trombone technique could help overcome this problem. Covered stents come in even smaller diameters than endograft limbs and usually fail to exclude large caliber iliac landing zones. In order to address this issue, Klonaris et al.⁹³ deployed an inverted Zenith iliac limb. This technique is best suited for isolated CIAAs with a proximal landing zone within the CIA (with a diameter ~14 mm) and the distal landing zone within the EIA (with a diameter ~9 mm).

Hybrid Procedures

A hybrid procedure involves revascularization of at least one IIA during endovascular repair of an aortoiliac aneurysm or an isolated CIAA; this is usually applied in bilateral disease. The aneurysm is excluded using a covered stent or stent-graft, and ipsilateral IIA reperfusion is performed by means of open surgical reconstruction through a retroperitoneal or retroinguinal approach. IIA reperfusion is accomplished by IIA transposition

or bypass grafting originating from the distal portion of the endograft. This procedure has previously been applied in order to facilitate the endoluminal treatment of multisegmental AAAs.⁹⁴ Faries et al.⁹⁵ reported favorable short-term results in patients whose AAA anatomy required extension of the endograft into the EIA. Before endovascular aneurysm repair (EVAR), IIA bypass was successfully applied for patients with bilateral buttock claudication.⁹⁶ The use of a retroperitoneal incision was associated with greater blood loss, longer procedural times and hospital stays, and higher complication rates. Arko et al.⁹⁷ compared IIA bypass versus IIA embolization and found a 50% incidence of buttock claudication with embolization and no claudication after bypass. Additionally, a series by Lee et al.⁹⁸ including 57 patients undergoing bypass reported no ischemic complications in the pelvis. Overall, primary patency rates range between 91% and 100% in 3 years⁹⁸; the main disadvantage of this approach is the complexity of the procedure. The technique should be reserved for fit patients without contraindications for open repair and mainly for bilateral iliac aneurysms with indispensable IIAs.

Lastly, Hinchliffe et al.⁵⁴ proposed another interesting hybrid procedure involving the deployment of an aortoiliac endograft that lands distally at or just beyond the CIA bifurcation, followed by sewing the graft directly to the CIA bifurcation via an extraperitoneal approach.

“Bell-Bottom” or “Flared” Iliac Limbs Technique

The “bell-bottom” technique was proposed for endovascular repair of AAAs with concomitant ectatic but non-aneurysmal CIAs. Initially, it involved the deployment of aortic tubular cuffs as distal extensions beyond the iliac limbs of the aortic graft in order to seal the ectatic CIAs.^{49,50} Later on, “bell-bottom” iliac limbs were made commercially available, incorporating distal diameters up to 28 mm (depending upon the manufacturer). This technique can be used in isolated IIAs as well as part of EVAR for an AAA with a

bifurcated endograft. The main indication is in bilateral CIAAs where at least one IIA should be preserved.

Endovascular EIA-to-IIA Bypass

This technique was initially proposed by Hoffer et al.⁹⁹ in 1999. Bergamini et al.¹⁰⁰ used it to treat 4 patients with AAA and bilateral CIAAs. The AAA was repaired with an aorto-monoiliac device extending from the infrarenal neck up to the EIA. The ipsilateral CIAAs were treated by coil embolization of the IIA and extension of the endograft to the EIA. The contralateral CIAAs were excluded using a custom-made stent-graft or a commercial stent-graft extending from the EIA to the IIA, which preserved pelvic inflow via retrograde perfusion from the femorofemoral bypass. The endoluminal EIA-to-IIA endografts remained patent during midterm follow-up. The technique can be used in unilateral aortoiliac aneurysms or unilateral isolated CIAAs extending to the iliac bifurcation. In unilateral CIAAs, the aortomonoiliac endograft is deployed toward the contralateral non-aneurysmal CIA so that the contralateral IIA receives antegrade perfusion and the ipsilateral IIA is reperfused by a reversed U-shaped self-expanding covered stent from the ipsilateral EIA via a femorofemoral bypass.^{101,102} The main advantage for unilateral CIAAs is that both IIAs are reperfused; for bilateral CIAAs, at least 1 IIA remains patent. However, the procedure is complex and it does involve an extra-anatomical bypass. For these reasons it is advised to use it only when the IIA is considered indispensable. An important prerequisite is that the angle between the IIA and EIA allows the EIA-to-IIA device to be deployed without significant kinking or angulation.

Antegrade Endovascular IIA Perfusion and Femorofemoral Bypass

Delle et al.¹⁰³ employed this technique to treat 4 patients with AAA and bilateral CIAAs. One of the IIAs was embolized with a coil and its orifice was covered with one limb of a bifurcated endograft that extended to the ipsilateral EIA. The contralateral IIA was reperfused by extending the ipsilateral limb

of the bifurcated device toward the IIA using covered stents via a brachial artery approach. A femorofemoral bypass supplied blood to the ipsilateral femoral artery. Using this configuration in bilateral CIAAs, one IIA can be reperfused. The technique can be modified to treat unilateral aortoiliac aneurysms or isolated CIAAs with the advantage of reperfusing both IIAs when they are both considered indispensable. The main disadvantage is the need for an extra-anatomical femorofemoral bypass.

A similar alternative was proposed by Leon et al.^{104,105} to repair a unilateral para-anastomotic CIAA because the inferior mesenteric artery and contralateral IIA had already been occluded. Other interventionists also described the use of 3 telescopically-overlapping covered endoprostheses to bridge a bifurcated aortic endograft with an IIA.^{106,107}

Modified Chimney Graft, Double-Barrel, or Sandwich Techniques for IIA Reperfusion

The "chimney graft" technique has been previously applied to preserve both renal arteries in AAAs with short proximal necks as an alternative to fenestrated grafts.¹⁰⁸ A modification of this can be applied in bilateral CIAAs or aortoiliac aneurysms. In such cases (bilateral CIAAs), one IIA can be embolized with a coil and its orifice can be covered with one of the limbs of a bifurcated aortic endograft, while the contralateral IIA and ipsilateral EIA can be reperfused by deploying two overlying covered stents (chimney graft, double-barrel, or sandwich techniques) within the limb of the bifurcated device.¹⁰⁹

Iliac Side Branch

These grafts consist of a side branch mounted on the medial side of an endoluminal iliac limb; covered stents are used to bridge the distance between the side branch and the IIA through a contralateral iliac access. The device is typically applied for rescuing an IIA, but it can be used for bilateral CIAAs, which allows the exclusion of aortoiliac aneurysms using a simple proximal extension of a bifurcated endograft.

Two different types of iliac side branches have been proposed, both of them based on the modular Zenith platform. The first is the Zenith iliac bifurcation device (IBD), or Zenith bifurcated iliac stent, that has a short straight side branch and is based on the configuration described by Abraham et al.¹¹⁰ in 2003. The device has been used in aortoiliac and CIA aneurysms with a technical success rate of 58% to 85%.^{111,112} In a series of 46 patients followed for 26 months, 11% of the patients developed branch occlusion; no rupture, aneurysm-related death, endoleak, migration, or dislocation was reported.¹¹² Other investigators have reported technical success rates of 91% to 100% and primary patency rates of 74% to 100% during a 6- to 20-month follow-up period.^{111,113-120}

The second type of Zenith iliac branch device is called "the helical branch."¹²¹ The elongated iliac side branch is helical in configuration to provide a longer sealing zone with the bridging stents and better absorption of the pulsatile forces. The results of a multicenter prospective study in 52 patients treated with 53 devices were promising: the technical success rate was 94%, with no endoleaks or component separations.¹²² However, 11% of the branches had occluded within the first month. Ferreira et al.¹²³ recently reported similar results.

The main advantage of both devices is IIA patency; disadvantages include the higher cost, delay between order and construction, and the complexity of the procedure. It is advisable to use this device when there is enough intrasac space for the branch to be deployed. The technique is probably better suited for large CIAAs that extend up to the iliac bifurcation.

An important issue when using the IIA as a distal landing zone, such as when deploying an iliac side branch, performing an EIA-to-IIA bypass, or perfusing the IIA in an antegrade manner, is the diameter and the length of non-aneurysmal IIA. There should be >20 mm of non-aneurysmal IIA with a diameter <15 mm, which means that in categories B2 and D2, when the aneurysm extends distally into the IIA leaving <20 mm of unaffected vessel wall and when the diameter of the proposed landing

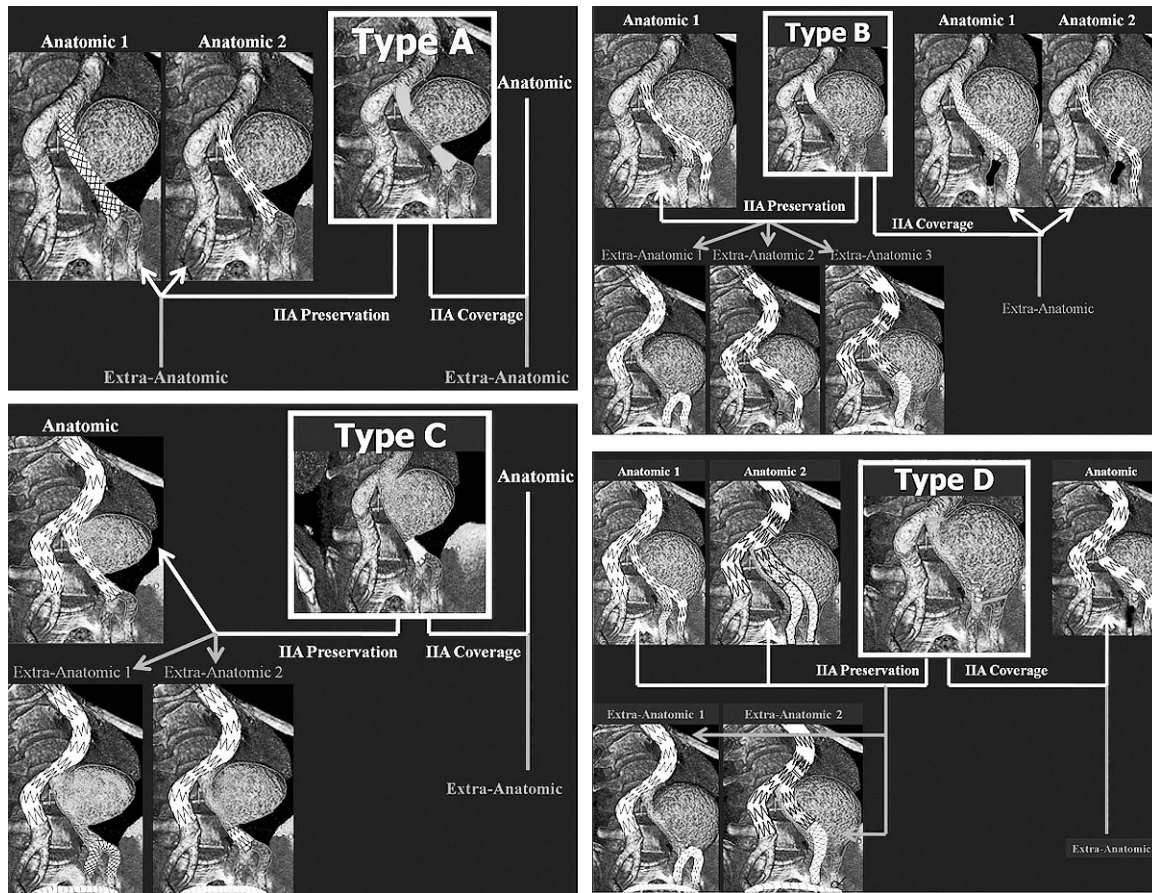


Figure 4 ♦ Proposed endoluminal solutions for types A–D isolated CIA aneurysms.

zone is >15 mm, this segment cannot be utilized as a landing zone for endovascular repair.

ENDOVASCULAR TECHNIQUES BY ANEURYSM TYPE

Endovascular and hybrid repairs or isolated CIAAs include procedures that allow either unilateral or bilateral preservation of IIA perfusion, which can be achieved via an anatomical or an extra-anatomical “pathway” (involving an extra-anatomical bypass using endoluminal devices or open reconstruction).

Type A: direct aneurysm exclusion can be achieved using covered stents (self-expanding or balloon-expandable) or with direct aneurysm exclusion using the iliac limbs of an aortic endograft (Fig. 4, Type A). Two overlapping devices (“trombone” technique) can be de-

ployed to ensure that the entire length of the proximal and distal fixation zone will be used.

Type B: Preserving IIA inflow: both anatomical and extra-anatomical solutions are feasible. Deployment of an iliac side branch device (Fig. 4, Type B: IIA preservation, anatomic 1) avoids the need for an extra-anatomical bypass, but there are several extra-anatomical alternatives. (1) Deployment of an aortomonoiliac endograft in the contralateral non-aneurysmal CIA with a femorofemoral crossover bypass and endograft deployment from the ipsilateral EIA to the ipsilateral IIA (Fig. 4, Type B: IIA preservation, extra-anatomic 1). (2) Deployment of a bifurcated endograft with ipsilateral extension to the EIA, ipsilateral retroperitoneal open surgical ligation of the IIA, and bypass grafting from the ipsilateral distal EIA to the ipsilateral IIA (Fig. 4, Type B: IIA preservation, extra-anatomic 2). (3)

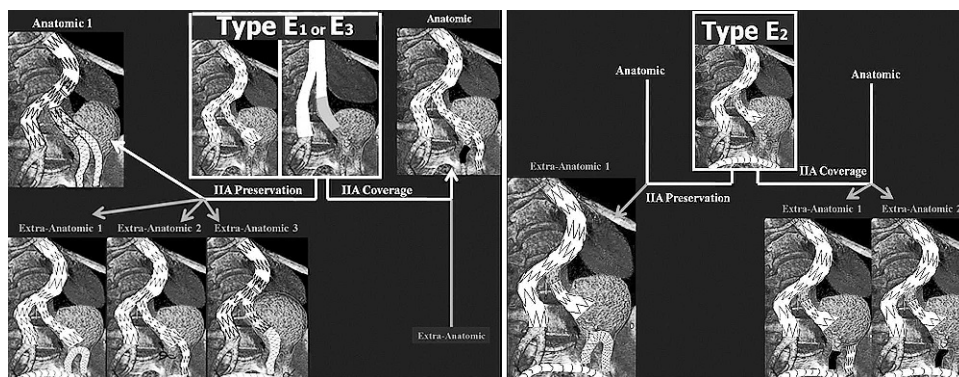


Figure 5 ♦ Proposed endoluminal solutions for types E1–E3 isolated CIA aneurysms.

Deployment of a bifurcated endograft with an ipsilateral iliac limb extension toward the ipsilateral IIA and adjunctive femorofemoral bypass and distal EIA ligation (Fig. 4, Type B: IIA preservation, extra-anatomic 3). In cases where the IIA could be sacrificed (covered), direct aneurysm exclusion is possible with covered stents or iliac limbs with IIA embolization (Fig. 4, Type B: IIA coverage, anatomic 1, 2).

Type C: Deployment of a bifurcated endograft with the ipsilateral iliac limb extending to the distal CIA landing zone (Fig. 4, Type C: IIA preservation, anatomic). When the deployment of an aortomonoiliac device is mandatory due to anatomical restrictions,^{65,66} the following configurations may be used. (1) Deployment of an aortomonoiliac endograft into the contralateral non-aneurysmal CIA with femorofemoral crossover bypass and an endograft extending from the ipsilateral EIA to the ipsilateral IIA (Fig. 4, Type C: IIA preservation, extra-anatomic 1). (2) Deployment of an aortomonoiliac device into the contralateral non-aneurysmal CIA with a femorofemoral crossover bypass and occlusion of the distal CIA before the bifurcation (Fig. 4, Type C: IIA preservation, extra-anatomic 2).

Type D: If IIA preservation is mandatory, the following configurations are possible: (1) deployment of an iliac side branch device (Fig. 4, Type D: IIA preservation, anatomic 1) and (2) a “double barrel” graft technique using a bifurcated device (Fig. 4, Type D: IIA preservation, anatomic 2). An adequate overlapping zone should exist between the 2 double-barrel grafts and the ipsilateral iliac

limb or stump to avoid type III endoleak.¹⁰⁸ Extra-anatomical solutions that preserve the IIA are: (1) aortomonoiliac endograft deployment into the contralateral non-aneurysmal CIA followed by a femorofemoral crossover bypass and deployment of an endograft from the ipsilateral EIA to the ipsilateral IIA (Fig. 4, Type D: IIA preservation, extra-anatomic 1) and (2) bifurcated endograft deployment with an ipsilateral iliac limb extension into the ipsilateral IIA followed by a femorofemoral bypass and distal EIA ligation (Fig. 4, Type D: IIA preservation, extra-anatomic 2). In cases where the IIA could be sacrificed, direct aneurysm exclusion using a bifurcated endograft with ipsilateral extension to the ipsilateral EIA and ipsilateral IIA embolization is also possible (Fig. 4, Type D: IIA coverage, anatomic).

Type E1 or E3: A similar approach as in “type B” iliac aneurysms can be adopted.¹²⁴ The ipsilateral iliac limb [(from the primary implanted device (E1) or Y-prosthesis (E3)] will serve as a proximal landing zone. In order to obtain a distal landing zone, a modified double-barrel chimney graft technique can be employed, using 2 covered stents or iliac limbs proximally attached to the primary graft’s limb (Fig. 5, Type E1/E3: IIA preservation, anatomical solution 1). In this case, special attention should be focused on adequate overlapping between the 2 chimney grafts and the ipsilateral iliac limb to avoid endoleak (type III).

Various extra-anatomical configurations are feasible to preserve IIA perfusion. (1) Aortomonoiliac endograft deployment into the contralateral non-aneurysmal CIA or iliac limb deployment with a femorofemoral crossover

bypass and an endograft deployed from the ipsilateral EIA into the ipsilateral IIA (Fig. 5, Type E1/E3: IIA preservation, extra-anatomic 1). (2) Covered stent or iliac limb deployed proximally and attached onto the primary ipsilateral limb, with an ipsilateral extension to the EIA, ipsilateral retroperitoneal open surgical ligation of the IIA, and bypass grafting from the ipsilateral distal EIA to the ipsilateral IIA (Fig. 5, Type E1/E3: IIA preservation, extra-anatomic 2). (3) Covered stent deployed proximally and attached to the primary ipsilateral limb, with ipsilateral extension to the ipsilateral IIA with adjunctive femorofemoral bypass and distal EIA ligation (Fig. 5, Type E1/E3: IIA preservation, extra-anatomic 3). In cases where the IIA could be sacrificed, direct aneurysm exclusion with covered stents (self-expanding or balloon-expandable) or iliac limbs with ipsilateral IIA embolization would be less cumbersome and easily applicable (Fig. 5, Type E1/E3: IIA coverage, anatomic).

Type E2: the only feasible repair would be extra-anatomical. In order to preserve the IIA, an EIA-to-IIA endograft could be deployed (Fig. 5, Type E2: IIA preservation, extra-anatomic 1). When the angle between the EIA and IIA is sharp, IIA coverage is unavoidable by means of IIA embolization and EIA occlusion with an endoluminal occluder (Fig. 5, Type E2: IIA coverage, extra-anatomic 1) or with IIA embolization and EIA ligation (Fig. 5, Type E2: IIA coverage, extra-anatomic 2).

In cases of bilateral isolated CIAAs, the proposed solutions include a combination of all the aforementioned techniques. Special attention should be given to IIA preservation. Additionally, in the case of bilateral iliac aneurysmal disease, a combined 1- or 2-stage procedure (open reconstruction on the one side followed by endoluminal repair contralaterally) is also feasible.¹²⁵

CONCLUSION

Given the high morbidity and mortality accompanying open reconstruction of isolated CIAAs, vascular specialists evolved a variety of endoluminal or hybrid techniques to repair such aneurysms. Most of these techniques have been evaluated in sporadic case reports or

larger retrospective series, with favorable short and midterm results. Some investigators attempted to directly compare the results of open versus endovascular repair; however, there is a serious need for a randomized multicenter prospective study.

This article has attempted to define the "suitable" iliac landing zone (proximal and distal) for endovascular repair based upon various studies. Additionally, we provide a review of all the possible endovascular solutions and techniques, as well as a systematic classification of uni- and bilateral isolated CIA aneurysms according to the "suitable" landing zone.

REFERENCES

1. Armon MP, Wenham PW, Whitaker SC, et al. Common iliac artery aneurysms in patients with abdominal aortic aneurysms. *Eur J Vasc Endovasc Surg.* 1998;15:255-257.
2. Brunkwall J, Hauksson H, Bengtsson H, et al. Solitary aneurysms of the iliac arterial system: an estimate of their frequency of occurrence. *J Vasc Surg.* 1989;10:381-384.
3. Lowry SF, Kraft RO. Isolated aneurysms of the iliac artery. *Arch Surg.* 1978;113:1289-1293.
4. Rignault DS. Isolated aneurysms of the hypogastric artery [in French]. *Bull Mem Soc Chir Paris.* 1967;57:167-175.
5. Nachbur BH, Inderbitzi RG, Bar W. Isolated iliac aneurysms. *Eur J Vasc Surg.* 1991;5:375-381.
6. Richardson JW, Greenfield LJ. Natural history and management of iliac aneurysms. *J Vasc Surg.* 1988;8:165-171.
7. Krupski WC, Selzman CH, Florida R, et al. Contemporary management of isolated iliac aneurysms. *J Vasc Surg.* 1998;28:1-13.
8. Kalyanasundaram A, Elmore JR, Manazer JR, et al. Simvastatin suppresses experimental aortic aneurysm expansion. *J Vasc Surg.* 2006;43:117-124.
9. Saratzis A, Kitas GD, Saratzis N, et al. Can statins suppress the development of abdominal aortic aneurysms? A review of the current evidence. *Angiology.* 2010;61:137-144.
10. Cardon JM, Cardon A, Joyeux A, et al. Endovascular repair of iliac artery aneurysm with Endoprosthesis I: a multicentric French study. *J Cardiovasc Surg (Torino).* 1996;37 (3 Suppl 1):45-50.
11. Razavi MK, Dake MD, Semba CT, et al. Percutaneous endoluminal placement of stent grafts for the treatment of isolated iliac aneurysms. *Radiology.* 1995;197:801-804.

12. Ruebben A, Tettoni S, Muratore P, et al. Percutaneous endoluminal bypass of iliac aneurysms with a covered stent. *Cardiovasc Intervent Radiol*. 1998;21:339-342.
13. Brin BJ, Busuttill RW. Isolated hypogastric artery aneurysms. *Arch Surg*. 1982;117:1329-1333.
14. Bolin T, Lund K, Skau T. Isolated aneurysms of the iliac artery: what are the chances of rupture? *Eur J Vasc Surg*. 1988;2:213-215.
15. Santilli SM, Wernsing SE, Lee ES. Expansion rates and outcomes for iliac artery aneurysms. *J Vasc Surg*. 2000;31(1 Pt 1):114-121.
16. Sandhu RS, Pipinos II. Isolated iliac artery aneurysms. *Semin Vasc Surg*. 2005;18:209-215.
17. Marin ML, Veith FJ, Lyon RT, et al. Transfemoral endovascular repair of iliac artery aneurysms. *Am J Surg*. 1995;170:179-182.
18. Michel C, Laffy PY, Leblanc G, et al. Percutaneous treatment of iliac aneurysms with endovascular stented grafts [in French]. *J Radiol*. 1996;77:433-436.
19. Christensen L, Justesen P, Larsen KE. Percutaneous transluminal treatment of an iliac pseudoaneurysm with endoprosthesis implantation. A case report. *Acta Radiol*. 1996;37:542-544.
20. Quinn SF, Sheley RC, Semonsen KG, et al. Endovascular stents covered with preexpanded polytetrafluoroethylene for treatment of iliac artery aneurysms and fistulas. *J Vasc Interv Radiol*. 1997;8:1057-1063.
21. Criado E, Marston WA, Ligush J, et al. Endovascular repair of peripheral aneurysms, pseudoaneurysms, and arteriovenous fistulas. *Ann Vasc Surg*. 1997;11:256-263.
22. Dorros G, Cohn JM, Jaff MR. Percutaneous endovascular stent-graft repair of iliac artery aneurysms. *J Endovasc Surg*. 1997;4:370-375.
23. Chemelli A, Hugl B, Klocker J, et al. Endovascular repair of isolated iliac artery aneurysms. *J Endovasc Ther*. 2010;17:492-503.
24. van Sambeek MR, van Urk H. Endovascular treatment of isolated iliac artery aneurysms [editorial]. *Eur J Vasc Endovasc Surg*. 1998;15:91-92.
25. Scheinert D, Schroder M, Steinkamp H, et al. Treatment of iliac artery aneurysms by percutaneous implantation of stent grafts. *Circulation*. 2000;102(19 Suppl 3):III253-258.
26. Pisco JM, Capita LM, Branco JC, et al. Endovascular treatment of iliac artery aneurysm [in Portuguese]. *Acta Med Port*. 2001;14:419-422.
27. Henry M, Amor M, Henry I, et al. Percutaneous endovascular treatment of peripheral aneurysms. *J Cardiovasc Surg*. 2000;41:871-883.
28. Mofid R, Otal P, Boyer L, et al. Common iliac aneurysms with short or absent proximal necks: endoluminal repair with a covered endoprosthesis. *Eur J Vasc Endovasc Surg*. 2003;26:334-336.
29. Saratzis N, Melas N, Saratzis A, et al. EndoFit stent-graft repair of isolated common iliac artery aneurysms with short necks. *J Endovasc Ther*. 2006;13:667-671.
30. Chaer RA, Barbato JE, Lin SC, et al. Isolated iliac artery aneurysms: a contemporary comparison of endovascular and open repair. *J Vasc Surg*. 2008;47:708-713.e1.
31. Patel NV, Long GW, Cheema ZF, et al. Open vs. endovascular repair of isolated iliac artery aneurysms: a 12-year experience. *J Vasc Surg*. 2009;49:1147-1153.
32. Bacharach JM, Slovut DP. State of the art: management of iliac artery aneurysmal disease. *Catheter Cardiovasc Interv*. 2008;71:708-714.
33. Bockler D, Schumacher H, Burger U, et al. Surgical management of isolated iliac aneurysms [in German]. *Zentralbl Chir*. 2006;131:18-24.
34. Fahrni M, Lachat MM, Wildermuth S, et al. Endovascular therapeutic options for isolated iliac aneurysms with a working classification. *Cardiovasc Intervent Radiol*. 2003;26:443-447.
35. Sakamoto I, Sueyoshi E, Hazama S, et al. Endovascular treatment of iliac artery aneurysms. *Radiographics*. 2005;25 Suppl 1: S213-227.
36. Patterson BO, Hinchliffe RJ, Holt PJ, et al. Importance of aortic morphology in planning aortic interventions. *J Endovasc Ther*. 2010;17:73-77.
37. Leurs LJ, Kievit J, Dagnelie PC, et al. Influence of infrarenal neck length on outcome of endovascular abdominal aortic aneurysm repair. *J Endovasc Ther*. 2006;13:640-648.
38. Bosman WM, van der Steenhoven TJ, Suarez DR, et al. The proximal fixation strength of modern EVAR grafts in a short aneurysm neck. An in vitro study. *Eur J Vasc Endovasc Surg*. 2010;39:187-192.
39. Elkouri S, Martelli E, Gloviczki P, et al. Most patients with abdominal aortic aneurysm are not suitable for endovascular repair using currently approved bifurcated stent-grafts. *Vasc Endovascular Surg*. 2004;38:401-412.
40. Hobo R, Kievit J, Leurs LJ, et al. Influence of severe infrarenal aortic neck angulation on complications at the proximal neck following endovascular AAA repair: a EUROSTAR study. *J Endovasc Ther*. 2007;14:1-11.
41. Hassen-Khodja R, Feugier P, Favre JP, et al. Outcome of common iliac arteries after

- straight aortic tube-graft placement during elective repair of infrarenal abdominal aortic aneurysms. *J Vasc Surg.* 2006;44:943-948.
42. Lavee J, Schneiderman J, Bass A, et al. Tube graft replacement of abdominal aortic aneurysm: is concomitant iliac disease a contraindication? *J Cardiovasc Surg (Torino).* 1988;29:449-452.
43. Provan JL, Fialkov J, Ameli FM, et al. Is tube repair of aortic aneurysm followed by aneurysmal change in the common iliac arteries? *Can J Surg.* 1990;33:394-397.
44. Hill AB, Ameli FM. Fate of the iliac arteries after repair of abdominal aortic aneurysm with an aortobifemoral bypass graft. *Ann Vasc Surg.* 1998;12:330-334.
45. Aljabri B, Obrand DI, Montreuil B, et al. Early vascular complications after endovascular repair of aortoiliac aneurysms. *Ann Vasc Surg.* 2001;15:608-614.
46. Henretta JP, Karch LA, Hodgson KJ, et al. Special iliac artery considerations during aneurysm endografting. *Am J Surg.* 1999;178:212-218.
47. Huang Y, Gloviczki P, Duncan AA, et al. Common iliac artery aneurysm: expansion rate and results of open surgical and endovascular repair. *J Vasc Surg.* 2008;47:1203-1211.
48. Melas N, ed. *Isolated Iliac Artery Aneurysms.* 12th Hellenic Congress of Angiology and Vascular Surgery: Athens, Greece, 2010.
49. Kritpracha B, Pigott JP, Russell TE, et al. Bell-bottom aortoiliac endografts: an alternative that preserves pelvic blood flow. *J Vasc Surg.* 2002;35:874-881.
50. Clarke MJ, Pimpalwar S, Wyatt MG, et al. Endovascular exclusion of bilateral common iliac artery aneurysms with preservation of internal iliac artery perfusion. *Eur J Vasc Endovasc Surg.* 2001;22:559-562.
51. McDonnell CO, Semmens JB, Allen YB, et al. Large iliac arteries: a high-risk group for endovascular aortic aneurysm repair. *J Endovasc Ther.* 2007;14:625-629.
52. Malagari K, Brountzos E, Gougoulakis A, et al. Large diameter limbs for dilated common iliac arteries in endovascular aneurysm repair: is it safe? *Cardiovasc Intervent Radiol.* 2004;27:237-242.
53. Karch LA, Hodgson KJ, Mattos MA, et al. Management of ectatic, nonaneurysmal iliac arteries during endoluminal aortic aneurysm repair. *J Vasc Surg.* 2001;33(2 Suppl):S33-38.
54. Hinchliffe RJ, Hopkinson BR. A hybrid endovascular procedure to preserve internal iliac artery patency during endovascular repair of aortoiliac aneurysms. *J Endovasc Ther.* 2002;9:488-492.
55. Lee WA, O'Dorisio J, Wolf YG, et al. Outcome after unilateral hypogastric artery occlusion during endovascular aneurysm repair. *J Vasc Surg.* 2001;33:921-926.
56. Yano OJ, Morrissey N, Eisen L, et al. Intentional internal iliac artery occlusion to facilitate endovascular repair of aortoiliac aneurysms. *J Vasc Surg.* 2001;34:204-211.
57. Karch LA, Hodgson KJ, Mattos MA, et al. Adverse consequences of internal iliac artery occlusion during endovascular repair of abdominal aortic aneurysms. *J Vasc Surg.* 2000;32:676-683.
58. Geraghty PJ, Sanchez LA, Rubin BG, et al. Overt ischemic colitis after endovascular repair of aortoiliac aneurysms. *J Vasc Surg.* 2004;40:413-418.
59. Iliopoulos JI, Howanitz PE, Pierce GE, et al. The critical hypogastric circulation. *Am J Surg.* 1987;154:671-675.
60. Lose G, Jorgensen L, Lorentzen JE. Regional ischemia due to compromised collateral circulation after arterial reconstruction. *Acta Chir Scand.* 1985;151:301-303.
61. Picone AL, Green RM, Ricotta JR, et al. Spinal cord ischemia following operations on the abdominal aorta. *J Vasc Surg.* 1986;3:94-103.
62. Parodi JC. Endovascular repair of abdominal aortic aneurysms and other arterial lesions. *J Vasc Surg.* 1995;21:549-557.
63. May J, White G, Waugh R, et al. Treatment of complex abdominal aortic aneurysms by a combination of endoluminal and extraluminal aortofemoral grafts. *J Vasc Surg.* 1994;19:924-933.
64. Hassen-Khodja R, Pittaluga P, Le Bas P, et al. Role of direct revascularization of the internal iliac artery during aortoiliac surgery. *Ann Vasc Surg.* 1998;12:550-556.
65. Pittaluga P, Batt M, Hassen-Khodja R, et al. Revascularization of internal iliac arteries during aortoiliac surgery: a multicenter study. *Ann Vasc Surg.* 1998;12:537-543.
66. Saratzis N, Melas N, Lazaridis J, et al. Endovascular AAA repair with the aortomonoiliac EndoFit stent-graft: two years' experience. *J Endovasc Ther.* 2005;12:280-287.
67. Lazaridis J, Melas N, Saratzis A, et al. Reporting mid- and long-term results of endovascular grafting for abdominal aortic aneurysms using the aortomonoiliac configuration. *J Vasc Surg.* 2009;50:8-14.
68. Iliopoulos JI, Hermreck AS, Thomas JH, et al. Hemodynamics of the hypogastric arterial circulation. *J Vasc Surg.* 1989;9:637-642.

69. Mehta M, Veith FJ, Ohki T, et al. Unilateral and bilateral hypogastric artery interruption during aortoiliac aneurysm repair in 154 patients: a relatively innocuous procedure. *J Vasc Surg.* 2001;33:S27-32.
70. Engelke C, Elford J, Morgan RA, et al. Internal iliac artery embolization with bilateral occlusion before endovascular aortoiliac aneurysm repair—clinical outcome of simultaneous and sequential intervention. *J Vasc Interv Radiol.* 2002;13:667-676.
71. Kritpracha B, Pigott JP, Price CI, et al. Distal internal iliac artery embolization: a procedure to avoid. *J Vasc Surg.* 2003;37:943-948.
72. Heye S, Nevelsteen A, Maleux G. Internal iliac artery coil embolization in the prevention of potential type 2 endoleak after endovascular repair of abdominal aortoiliac and iliac artery aneurysms: effect of total occlusion versus residual flow. *J Vasc Interv Radiol.* 2005;16:235-239.
73. Heye S. Preoperative internal iliac artery coil embolization for aneurysms involving the iliac bifurcation. *Acta Chir Belg.* 2006;106:144-148.
74. Lee C, Dougherty M, Calligaro K. Concomitant unilateral internal iliac artery embolization and endovascular infrarenal aortic aneurysm repair. *J Vasc Surg.* 2006;43:903-907.
75. Pellerin O, Caruba T, Kandounakis Y, et al. Embolization of the internal iliac artery: cost-effectiveness of two different techniques. *Cardiovasc Intervent Radiol.* 2008;31:1088-1093.
76. Rayt HS, Bown MJ, Lambert KV, et al. Buttock claudication and erectile dysfunction after internal iliac artery embolization in patients prior to endovascular aortic aneurysm repair. *Cardiovasc Intervent Radiol.* 2008;31:728-734.
77. Bharwani N, Raja J, Choke E, et al. Is internal iliac artery embolization essential prior to endovascular repair of aortoiliac aneurysms? *Cardiovasc Intervent Radiol.* 2008;31:504-508.
78. Farahmand P, Becquemin JP, Desgranges P, et al. Is hypogastric artery embolization during endovascular aortoiliac aneurysm repair (EVAR) innocuous and useful? *Eur J Vasc Endovasc Surg.* 2008;35:429-435.
79. Wyers MC, Schermerhorn ML, Fillinger MF, et al. Internal iliac occlusion without coil embolization during endovascular abdominal aortic aneurysm repair. *J Vasc Surg.* 2002;36:1138-1146.
80. Mell M, Tefera G, Schwarze M, et al. Absence of buttock claudication following stent-graft coverage of the hypogastric artery without coil embolization in endovascular aneurysm repair. *J Endovasc Ther.* 2006;13:415-419.
81. Rajasinghe HA, Pigott JP, Kritpracha B, et al. Internal iliac artery occlusion using a stent-graft tunnel during endovascular aneurysm repair: a new alternative to coil embolization. *J Endovasc Ther.* 2003;10:1082-1086.
82. Grenon SM, Gagnon J, Hsiang Y, et al. Occlusion of the common and internal iliac arteries for aortoiliac aneurysm repair: experience with the Amplatzer vascular plug. *Can J Surg.* 2009;52:E276-280.
83. Coupe NJ, Ling L, Cowling MG, et al. Treatment of a common iliac aneurysm by endovascular exclusion using the Amplatzer vascular plug and femorofemoral crossover graft. *Cardiovasc Intervent Radiol.* 2009;32:772-775.
84. Sanchez LA, Patel AV, Ohki T, et al. Midterm experience with the endovascular treatment of isolated iliac aneurysms. *J Vasc Surg.* 1999;30:907-913.
85. Parsons RE, Marin ML, Veith FJ, et al. Midterm results of endovascular stented grafts for the treatment of isolated iliac artery aneurysms. *J Vasc Surg.* 1999;30:915-921.
86. Sahgal A, Veith FJ, Lipsitz E, et al. Diameter changes in isolated iliac artery aneurysms 1 to 6 years after endovascular graft repair. *J Vasc Surg.* 2001;33:289-295.
87. Calvet P, Chabbert V, Chemla P, et al. Endoluminal treatment of peripheral aneurysm with covered endoprosthesis [in French]. *J Mal Vasc.* 2001;26:299-306.
88. Casana R, Nano G, Dalainas I, et al. Midterm experience with the endovascular treatment of isolated iliac aneurysms. *Int Angiol.* 2003;22:32-35.
89. Lagana D, Carrafiello G, Recaldini C, et al. Endovascular treatment of isolated iliac artery aneurysms: 2-year follow-up. *Radiol Med.* 2007;112:826-836.
90. Boules TN, Selzer F, Stanziale SF, et al. Endovascular management of isolated iliac artery aneurysms. *J Vasc Surg.* 2006;44:29-37.
91. Iseki H, Koizumi J, Tamura T, et al. Covered stent implantation by the puncture method for the treatment of a small aneurysm of the common iliac artery. *Jpn Circ J.* 2000;64:99-102.
92. Mukherjee D, Hashemi H. Percutaneous access with closure devices and iliac extension limbs allows safe repair of common iliac artery aneurysm repair as an outpatient procedure. *Vascular.* 2009;17:277-280.
93. Klonaris C, Verikokos C, Avgerinos ED, et al. Stent-graft repair of isolated iliac aneurysms with wide or ectatic necks with use of inverted Zenith device legs. *J Vasc Interv Radiol.* 2009;20:403-406.

94. Parodi JC, Ferreira M. Relocation of the iliac artery bifurcation to facilitate endoluminal treatment of abdominal aortic aneurysms. *J Endovasc Surg.* 1999;6:342-347.
95. Faries PL, Morrissey N, Burks JA, et al. Internal iliac artery revascularization as an adjunct to endovascular repair of aortoiliac aneurysms. *J Vasc Surg.* 2001;34:892-899.
96. Johansen K. Pelvic revascularization by direct hypogastric artery reconstruction. *Am J Surg.* 1996;171:456-459.
97. Arko FR, Lee WA, Hill BB, et al. Hypogastric artery bypass to preserve pelvic circulation: improved outcome after endovascular abdominal aortic aneurysm repair. *J Vasc Surg.* 2004;39:404-408.
98. Lee WA, Nelson PR, Berceli SA, et al. Outcome after hypogastric artery bypass and embolization during endovascular aneurysm repair. *J Vasc Surg.* 2006;44:1162-1168.
99. Hoffer EK, Nicholls SC, Fontaine AB, et al. Internal to external iliac artery stent-graft: a new technique for vessel exclusion. *J Vasc Interv Radiol.* 1999;10:1067-1073.
100. Bergamini RM, Rachel ES, Kinney EV, et al. External iliac artery-to-internal iliac artery endograft: a novel approach to preserve pelvic inflow in aortoiliac stent grafting. *J Vasc Surg.* 2002;35:120-124.
101. van Groenendaal L, Zeebregts CJ, Verhoeven EL, et al. External-to-internal iliac artery endografting for the exclusion of iliac artery aneurysms: an alternative technique for preservation of pelvic flow? *Catheter Cardiovasc Interv.* 2009;73:156-160.
102. Kotsis T, Tsanis A, Sfyroeras G, et al. Endovascular exclusion of symptomatic bilateral common iliac artery aneurysms with preservation of an aneurysmal internal iliac artery via a reverse-U stent-graft. *J Endovasc Ther.* 2006;13:158-163.
103. Delle M, Lönn L, Wingren U, et al. Preserved pelvic circulation after stent-graft treatment of complex aortoiliac artery aneurysms: a new approach. *J Endovasc Ther.* 2005;12:189-195.
104. Leon LR, Mills JL, Psalms SB, et al. A novel hybrid approach to the treatment of common iliac aneurysms: antegrade endovascular hypogastric stent grafting and femorofemoral bypass grafting. *J Vasc Surg.* 2007;45:1244-1248.
105. Leon LR, Psalms SB, Ilnat DM, et al. Endovascular common iliac aneurysm exclusion with antegrade hypogastric artery flow preservation: a novel approach. *Vascular.* 2008;16:106-111.
106. Pratesi G, Pulli R, Fargion A, et al. Alternative hybrid reconstruction for bilateral common and internal iliac artery aneurysms associated with external iliac artery occlusion. *J Endovasc Ther.* 2009;16:638-641.
107. Mertens RA, Bergoeing MP, Mariné LA, et al. Antegrade hypogastric revascularization during endovascular aortoiliac aneurysm repair: an alternative to bilateral embolization. *Ann Vasc Surg.* 2010;24:255.e9-12.
108. Ohrlander T, Sonesson B, Ivancev K, et al. The chimney graft: a technique for preserving or rescuing aortic branch vessels in stent-graft sealing zones. *J Endovasc Ther.* 2008;15:427-432.
109. Lobato AC. Sandwich technique for aortoiliac aneurysms extending to the internal iliac artery or isolated common/internal iliac artery aneurysms: a new endovascular approach to preserve pelvic circulation. *J Endovasc Ther.* 2011;18:106-111.
110. Abraham CZ, Reilly LM, Schneider DB, et al. A modular multi-branched system for endovascular repair of bilateral common iliac artery aneurysms. *J Endovasc Ther.* 2003;10:203-207.
111. Malina M, Dirven M, Sonesson B, et al. Feasibility of a branched stent-graft in common iliac artery aneurysms. *J Endovasc Ther.* 2006;13:496-500.
112. Ziegler P, Avgerinos ED, Umscheid T, et al. Branched iliac bifurcation: 6 years experience with endovascular preservation of internal iliac artery flow. *J Vasc Surg.* 2007;46:204-210.
113. Dias NV, Resch TA, Sonesson B, et al. EVAR of aortoiliac aneurysms with branched stent-grafts. *Eur J Vasc Endovasc Surg.* 2008;35:677-684.
114. Serracino-Inglott F, Bray AE, Myers P, et al. Endovascular abdominal aortic aneurysm repair in patients with common iliac artery aneurysms - Initial experience with the Zenith bifurcated iliac side branch device. *J Vasc Surg.* 2007;46:211-217.
115. Naik J, Hayes PD, Sadat U, et al. Internal iliac artery branch graft for common iliac artery aneurysm following previous open abdominal aortic aneurysm repair. *Eur J Vasc Endovasc Surg.* 2008;35:436-438.
116. Tielliu IF, Zeebregts CJ, van den Dungen JJ, Verhoeven EL. A modified technique for iliac artery branched endografting using a "tromboned" sheath. *J Vasc Surg.* 2008;48:1605-1608.
117. Oderich GS, Ricotta JJ. Novel surgeon-modified hypogastric branch stent-graft to preserve pelvic perfusion. *Ann Vasc Surg.* 2010;24:278-286.

118. Karthikesalingam A, Hinchliffe RJ, Holt PJ, et al. Endovascular aneurysm repair with preservation of the internal iliac artery using the iliac branch graft device. *Eur J Vasc Endovasc Surg.* 2010;39:285-294.
119. Lee WA. Branched endograft for aortoiliac artery aneurysms. *Vascular.* 2009;17 Suppl 3:S111-118.
120. Huilgol RL, Denton MJ, Cohen T. The iliac bifurcation device for endovascular iliac aneurysm repair: indications, deployment options and results at 1-year follow-up of 25 cases. *ANZ J Surg.* 2009;79:844-849.
121. Greenberg RK, West K, Pfaff K, et al. Beyond the aortic bifurcation: branched endovascular grafts for thoracoabdominal and aortoiliac aneurysms. *J Vasc Surg.* 2006;43:879-887.
122. Haulon S, Greenberg RK, Pfaff K, et al. Branched grafting for aortoiliac aneurysms. *Eur J Vasc Endovasc Surg.* 2007;33:567-574.
123. Ferreira M, Monteiro M, Lanziotti L. Technical aspects and midterm patency of iliac branched devices. *J Vasc Surg.* 2010;51:545-550.
124. Tsang JS, Naughton PA, Wang TT, et al. Endovascular repair of para-anastomotic aortoiliac aneurysms. *Cardiovasc Intervent Radiol.* 2009;32:1165-1170.
125. Franz RW, Knapp ED. Staged endovascular repair of bilateral internal iliac artery aneurysms. *Ann Vasc Surg.* 2009;23:136-138.