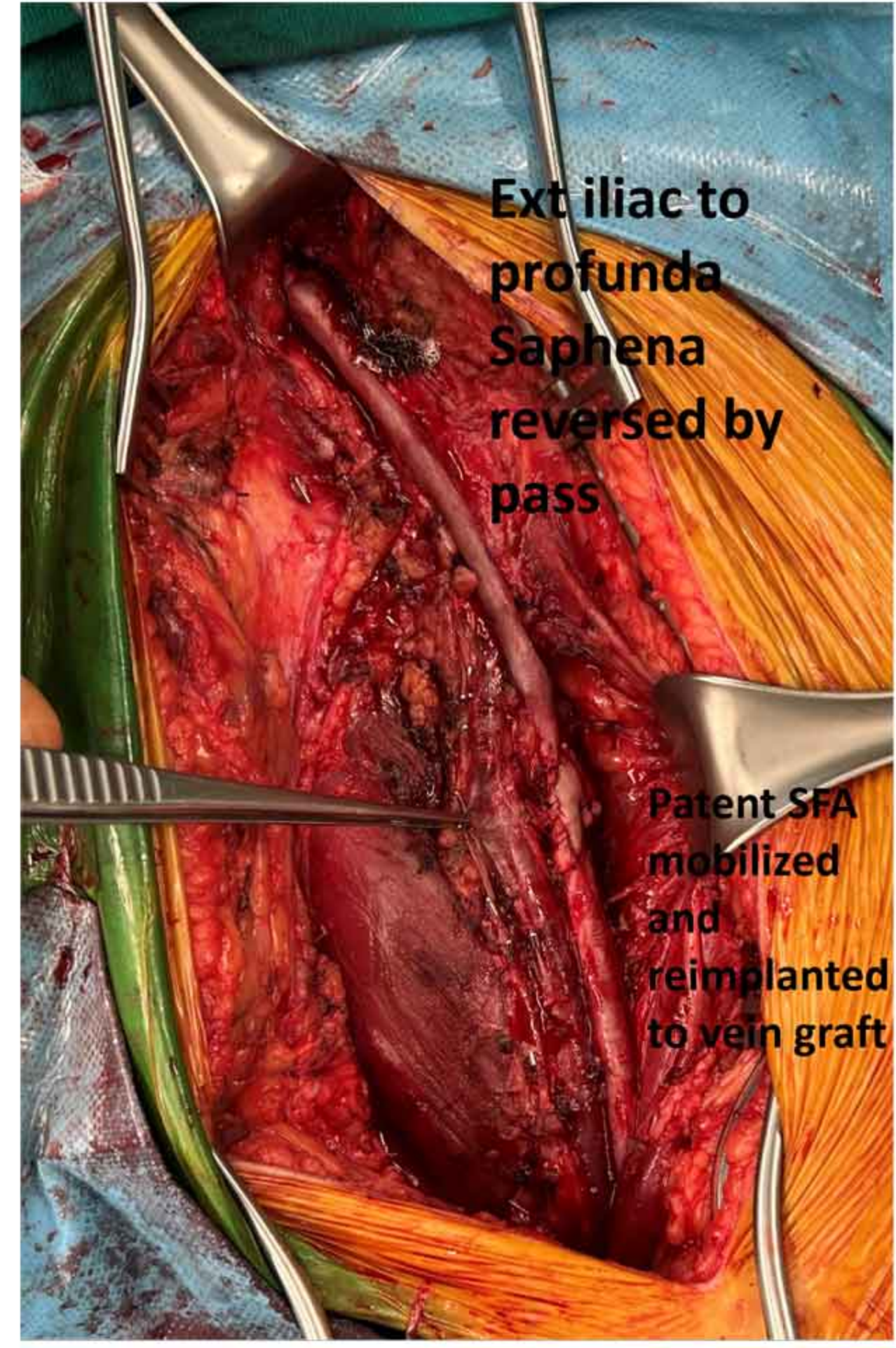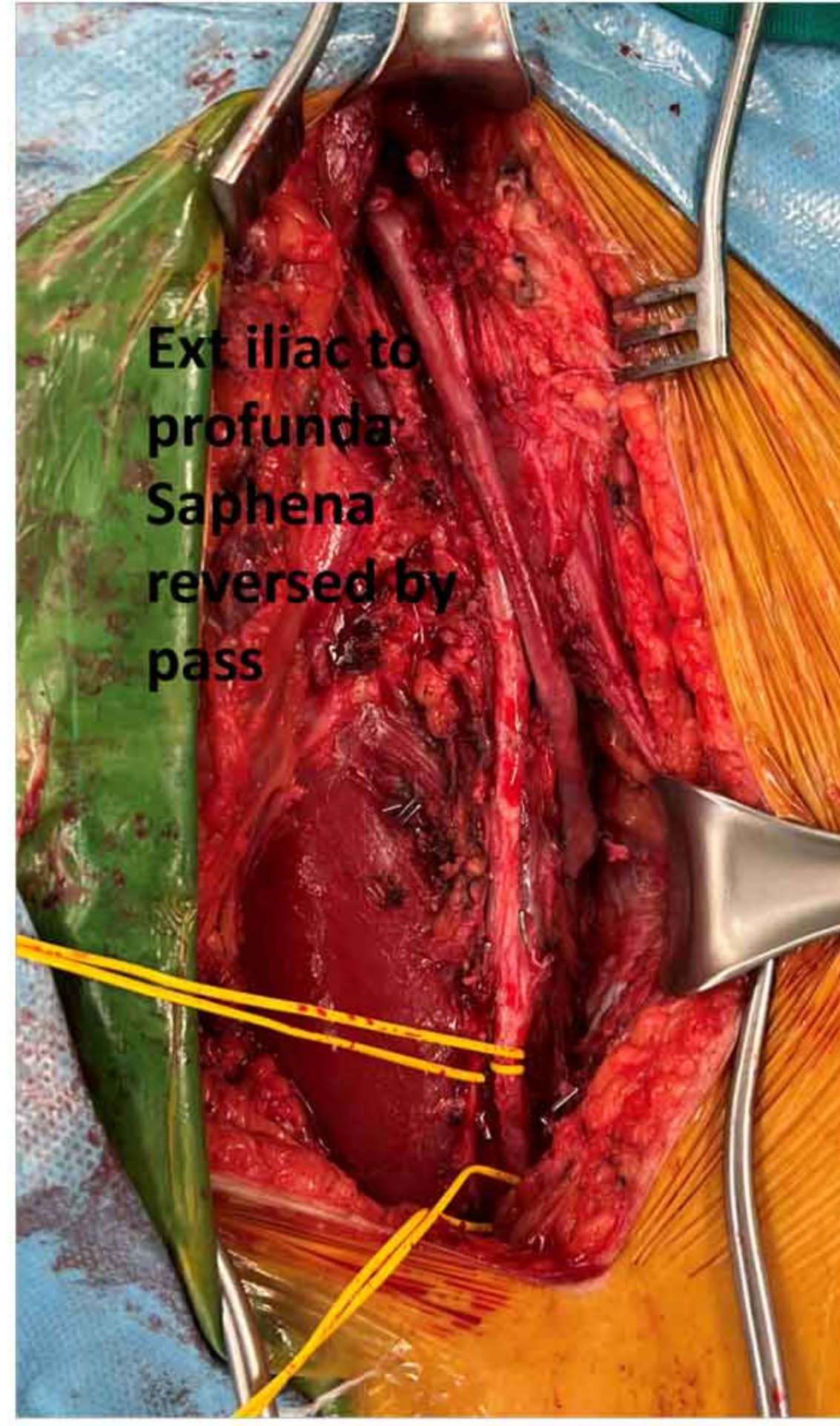
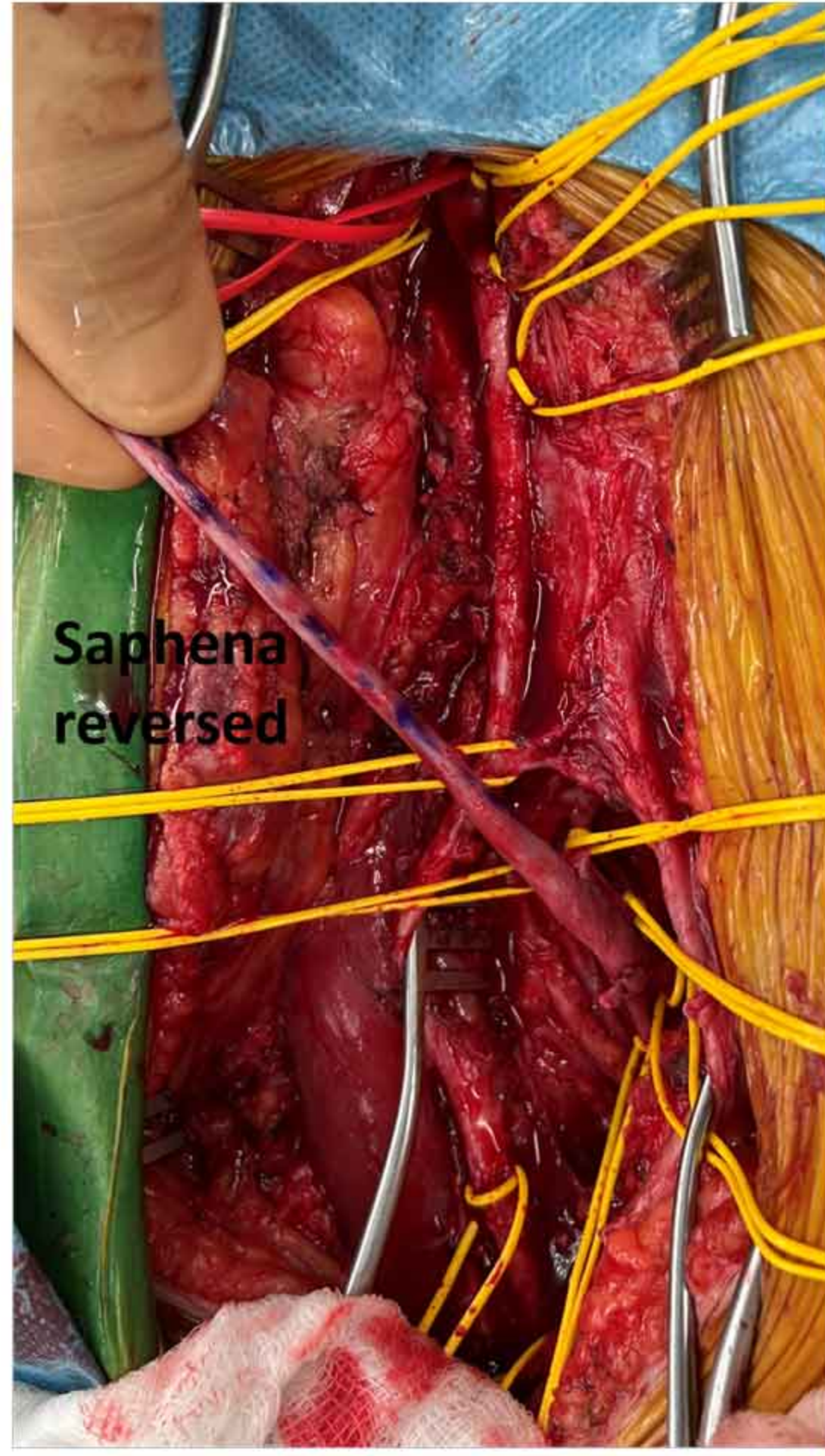
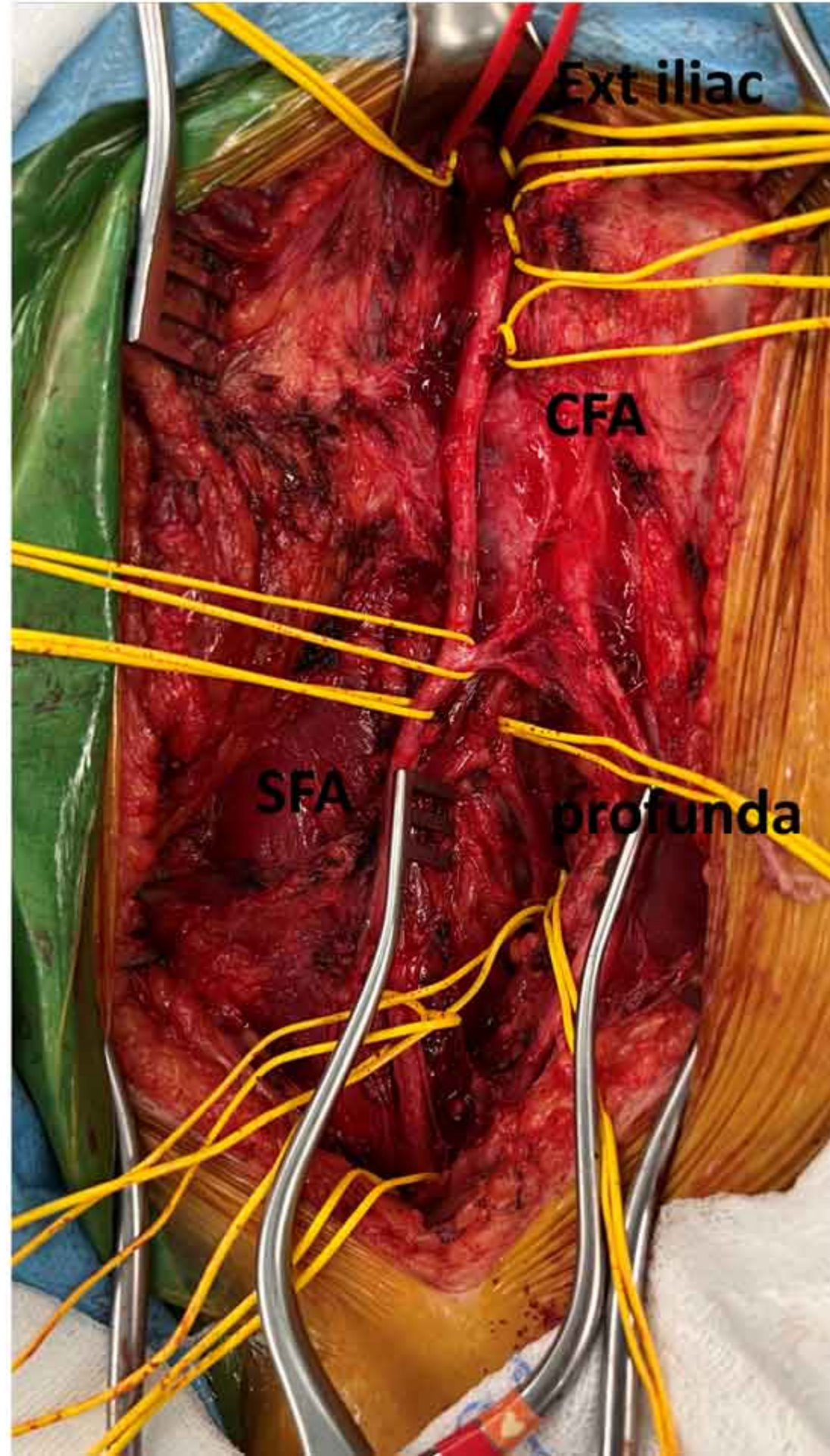
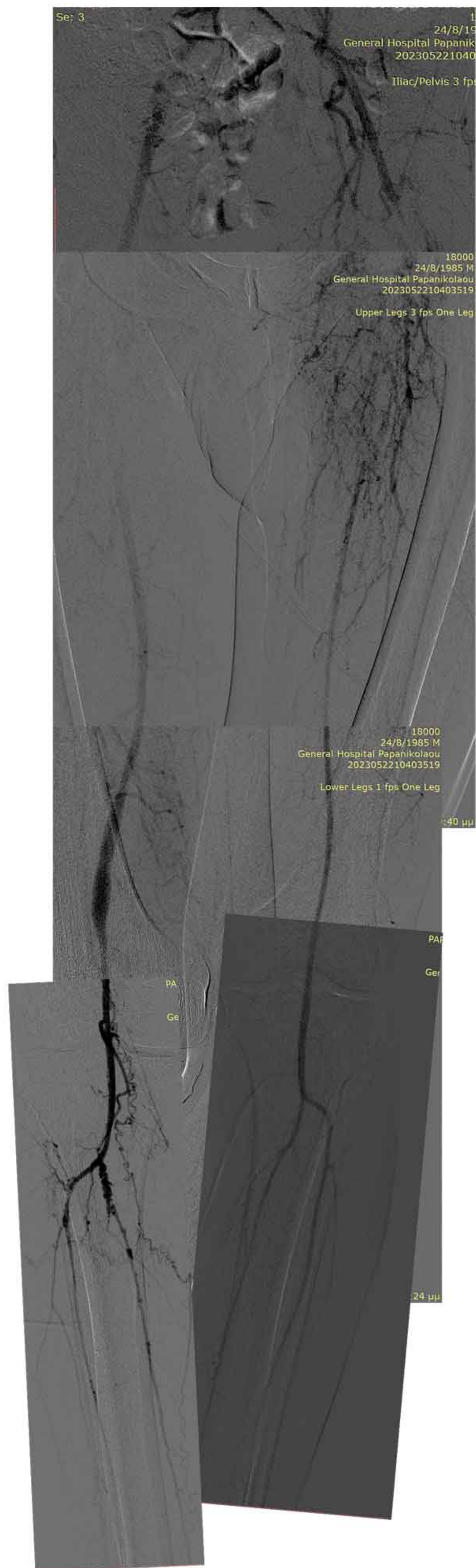
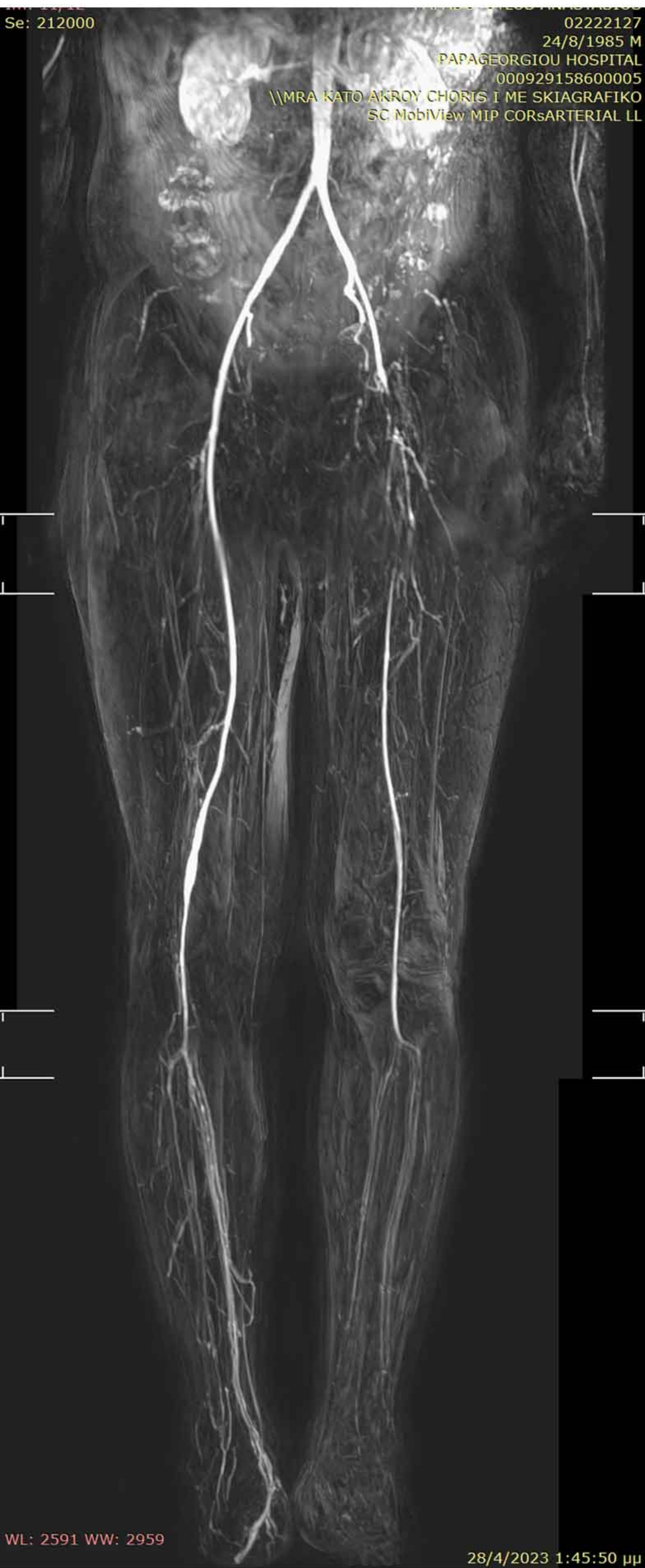

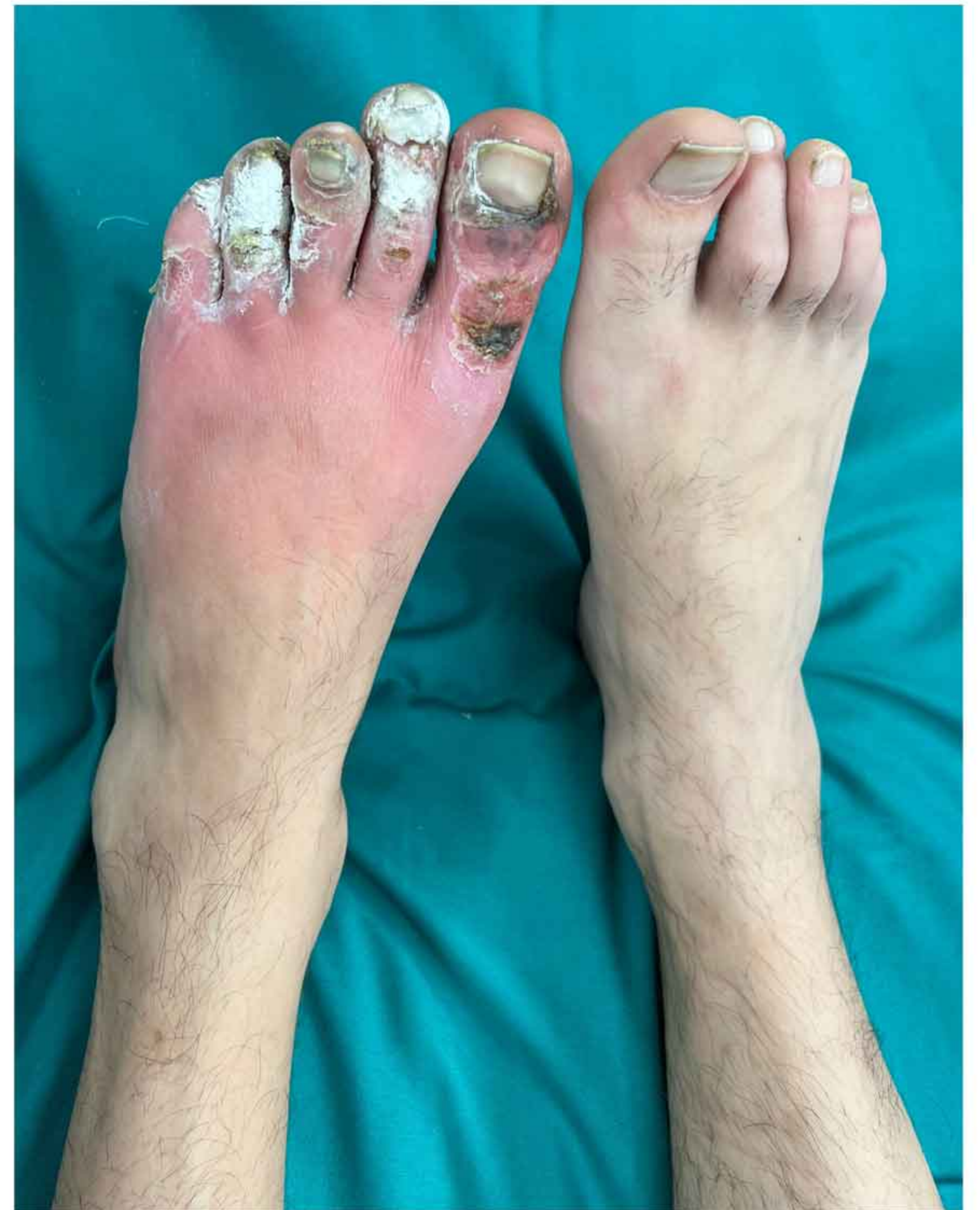
proximal arterial reconstruction with ext iliac to profunda femoris by pass (reversed saphenous vein) and SFA mobilization and reimplantation to the graft



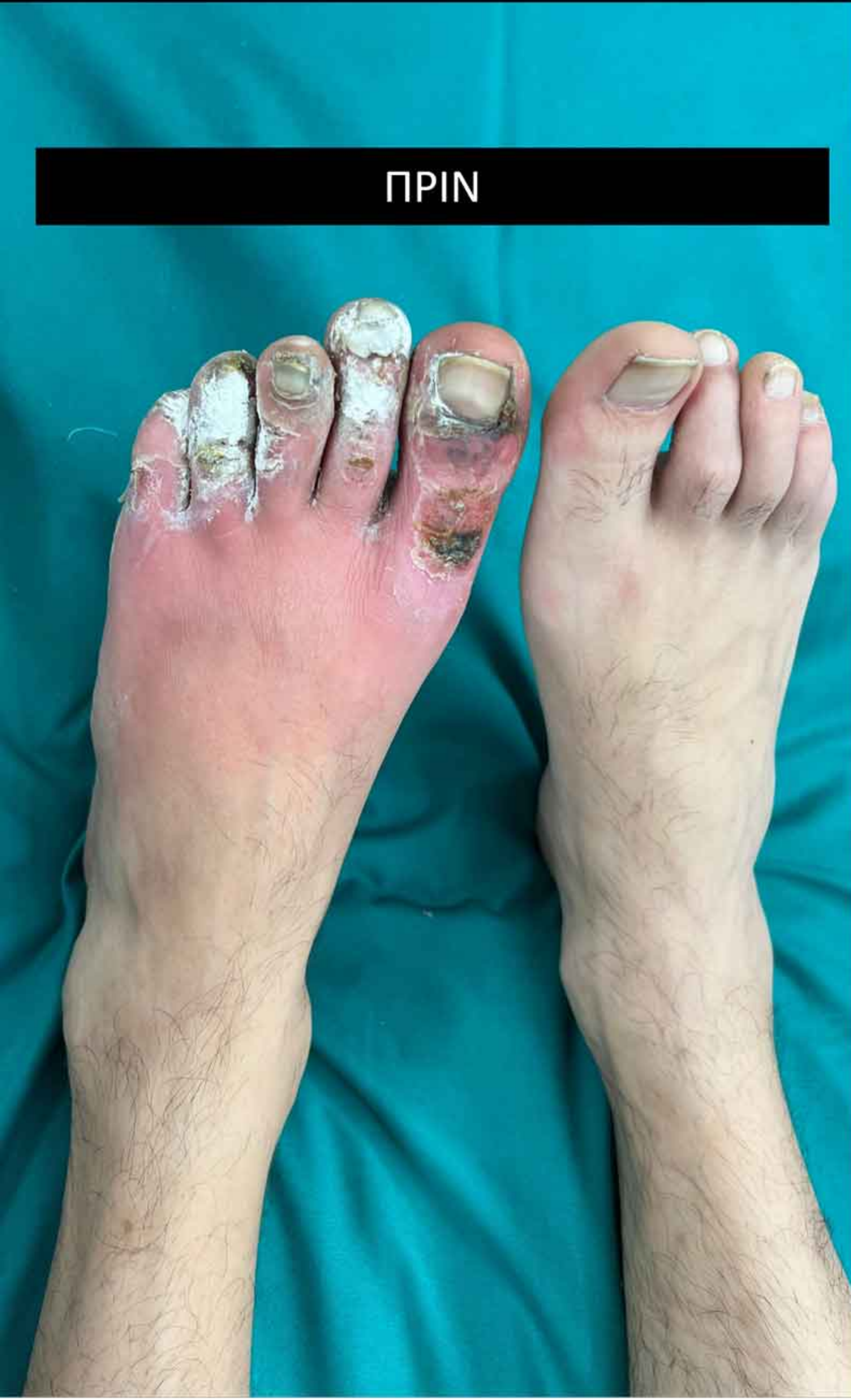

Buerger disease with left foot gangrene



ΝΟΣΟΣ BUERGER

ΠΡΙΝ



ΜΕΤΑ

